

# HOW DO I DEAL WITH DISTAL CONDUIT STENOSIS?

International Symposium on 3D Imaging for  
Interventional Catheterization in CHD (3DI3 Conference)

Martin Bocks, M.D.

Pediatric Interventional Cardiology

UH Rainbow Babies & Children's Hospital

The Congenital Heart Collaborative



**The Congenital  
Heart Collaborative** | University Hospitals  
Rainbow Babies & Children's  
Nationwide Children's Hospital



- ▶ Consultant/Proctor for Edwards Lifesciences

# DISCLOSURES



**The Congenital Heart Collaborative** | University Hospitals  
Rainbow Babies & Children's  
Nationwide Children's Hospital




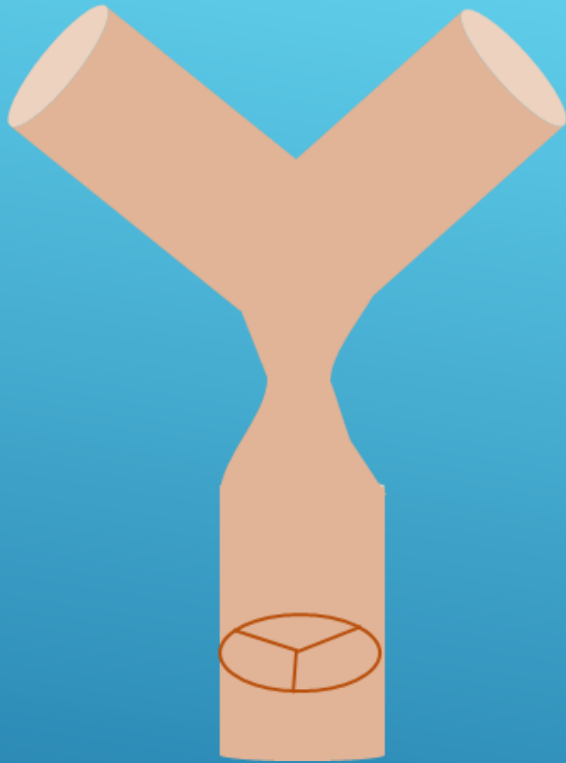
- ▶ Branch PS?
- ▶ Unilateral vs Bilateral?
- ▶ Close to valve?
- ▶ Valve competent ?
- ▶ Branch pulmonary artery hypoplasia?

# APPROACH



**The Congenital Heart Collaborative** | University Hospitals  
Rainbow Babies & Children's  
Nationwide Children's Hospital



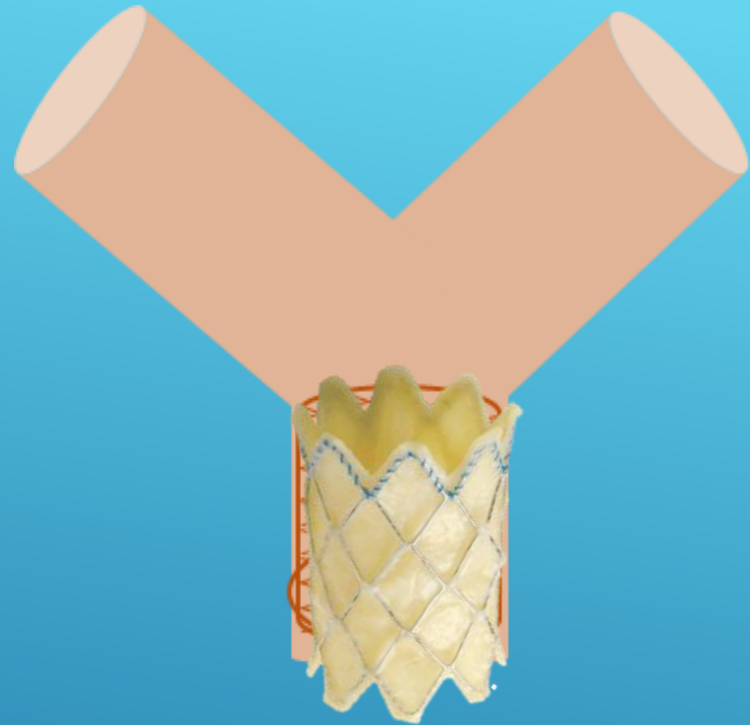
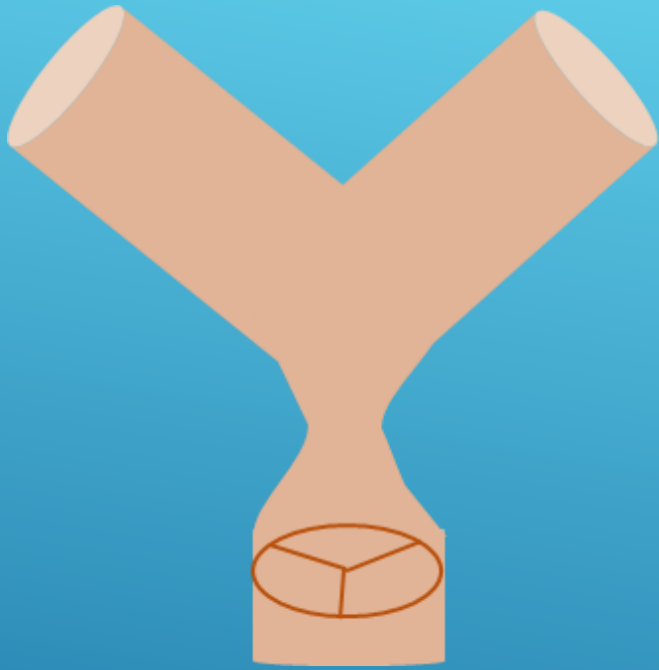


STENOSIS REMOTE FROM VALVE  
NO BRANCH PS



The Congenital Heart Collaborative | University Hospitals  
Rainbow Babies & Children's | Nationwide Children's Hospital



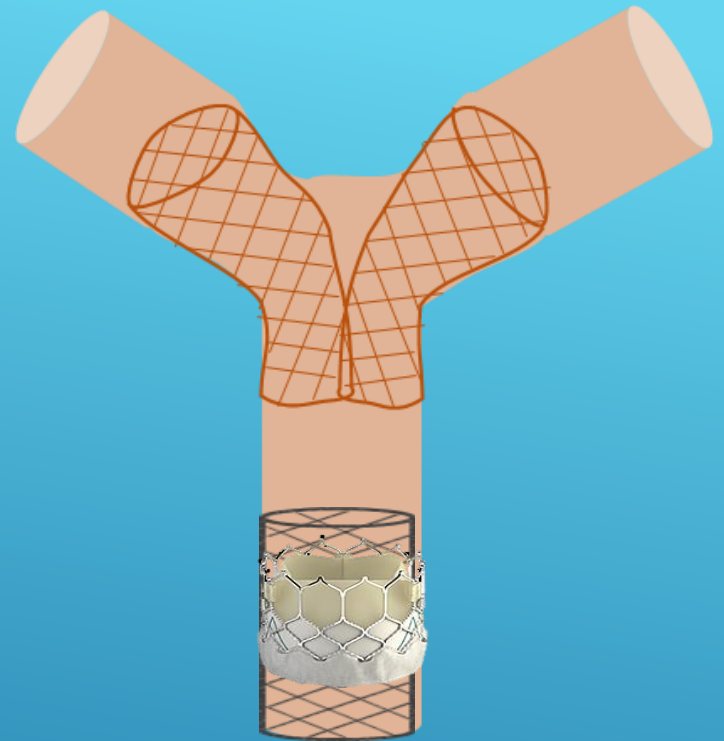
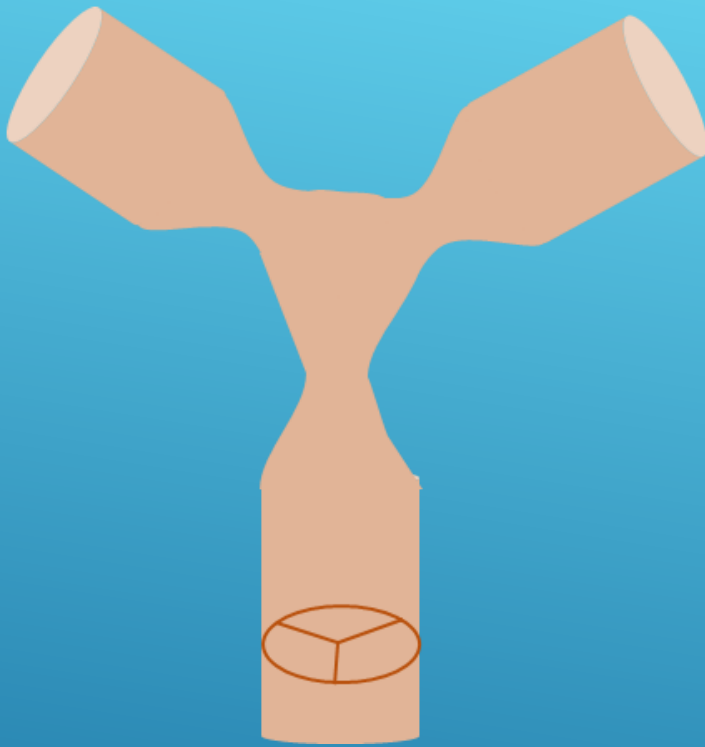


STENOSIS CLOSE TO VALVE/SHORT CONDUIT  
NO BRANCH PS



**The Congenital Heart Collaborative** | University Hospitals  
Rainbow Babies & Children's  
Nationwide Children's Hospital



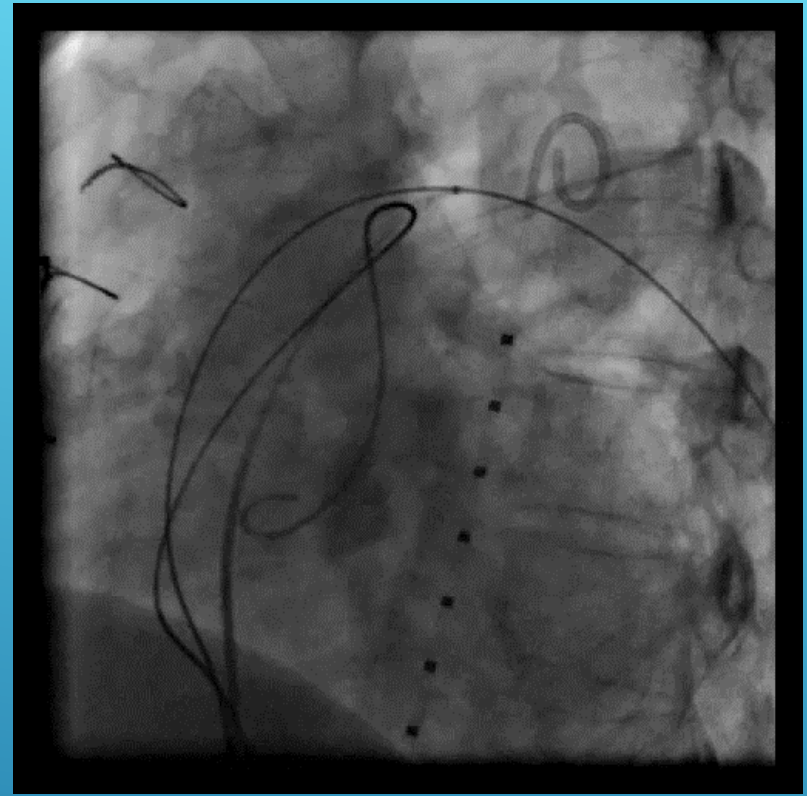
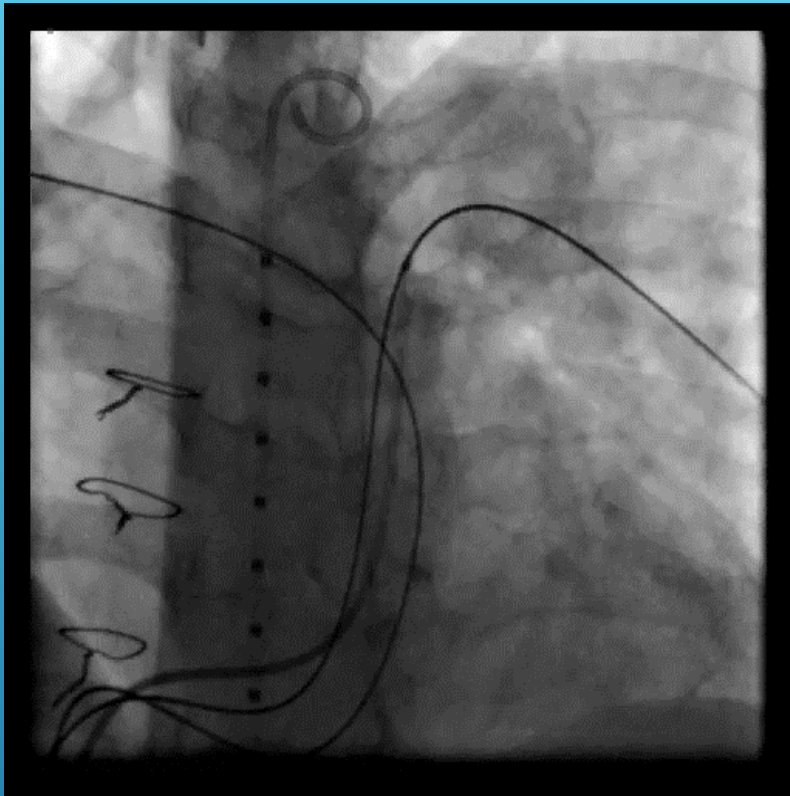


# STENOSIS REMOTE FROM VALVE BILATERAL BRANCH PS



**The Congenital Heart Collaborative** | University Hospitals  
Rainbow Babies & Children's  
Nationwide Children's Hospital





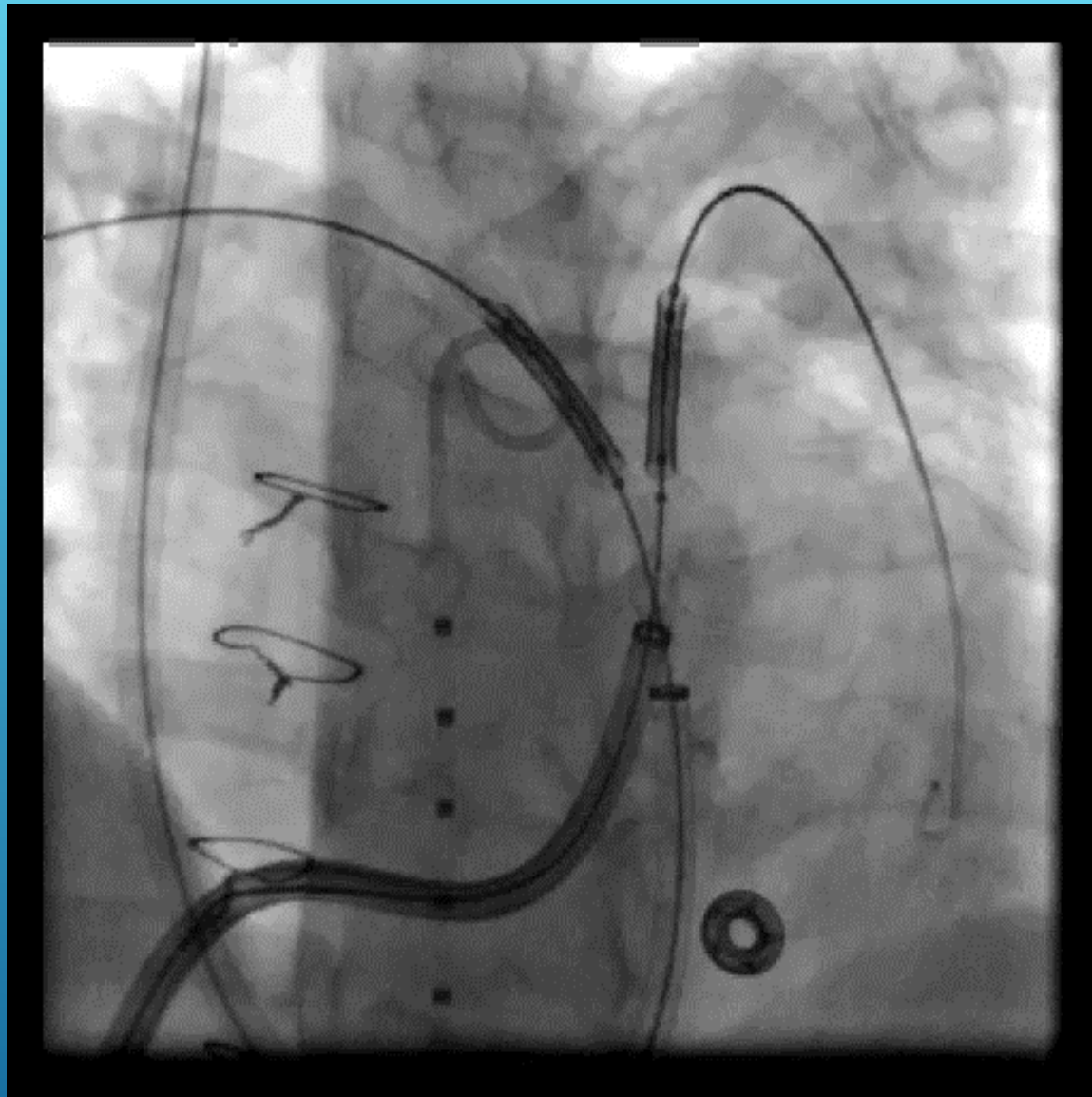
24 Y.O. WOMAN WITH DIGEORGE AND TRUNCUS  
ARTERIOSUS  
MODERATE B/L BRANCH PS AND MILD DISTAL  
CONDUIT STENOSIS  
MILD PI



The Congenital Heart Collaborative | University Hospitals  
Rainbow Babies & Children's  
Nationwide Children's Hospital





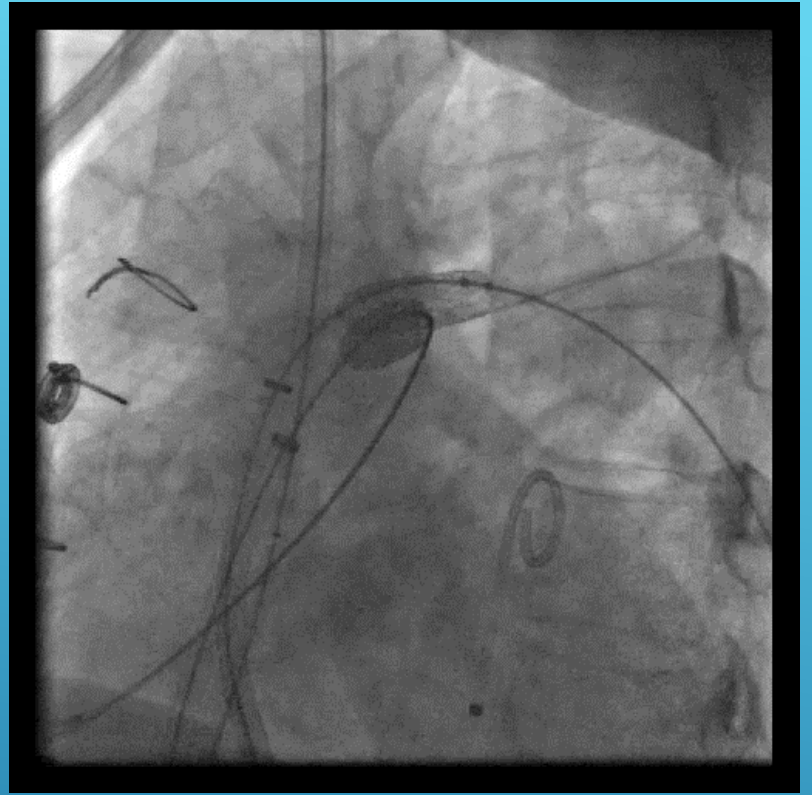
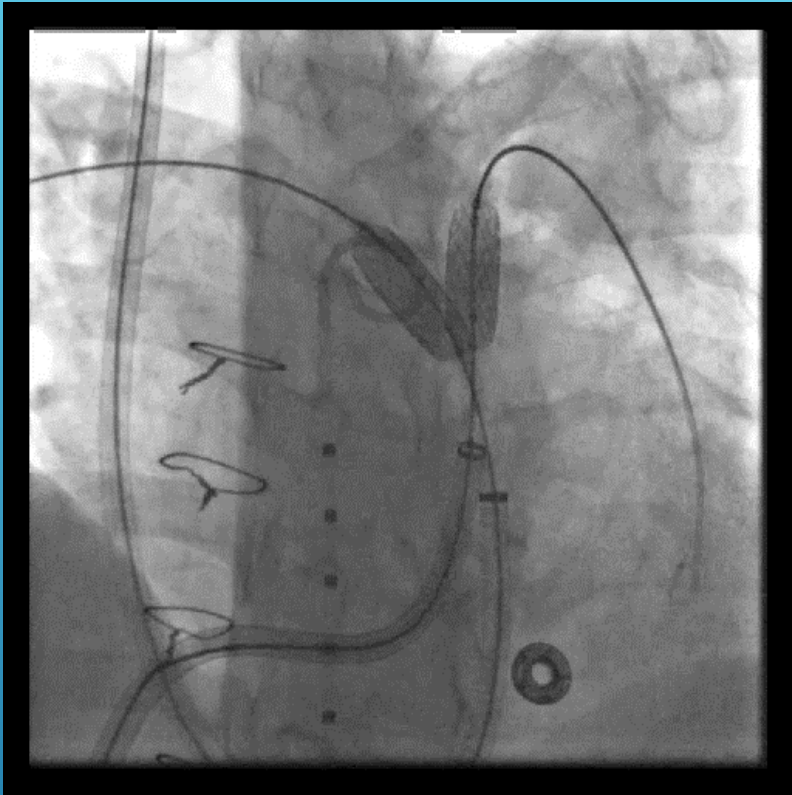


## The Congenital Heart Collaborative

University Hospitals  
Rainbow Babies & Children's  
Nationwide Children's Hospital



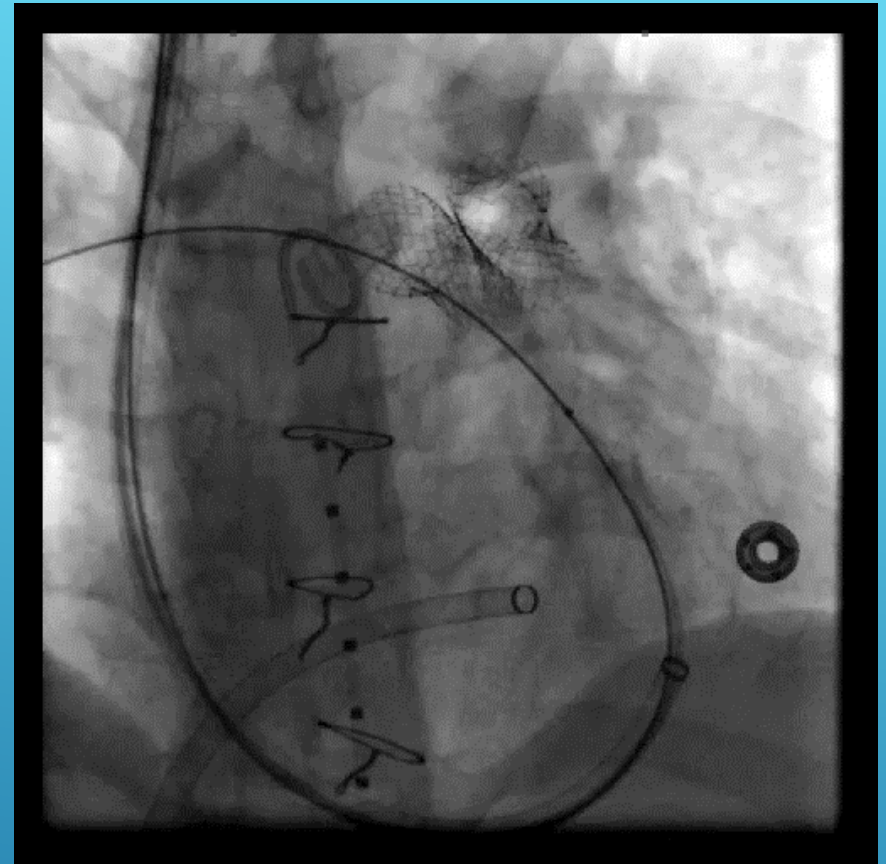
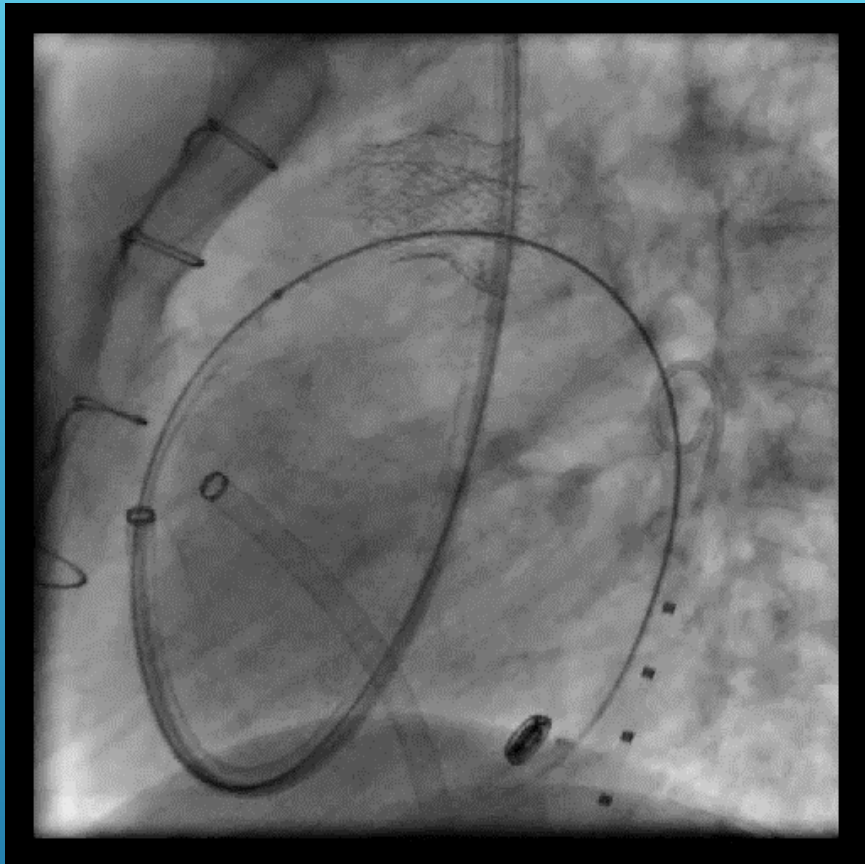




## The Congenital Heart Collaborative

University Hospitals  
Rainbow Babies & Children's  
Nationwide Children's Hospital

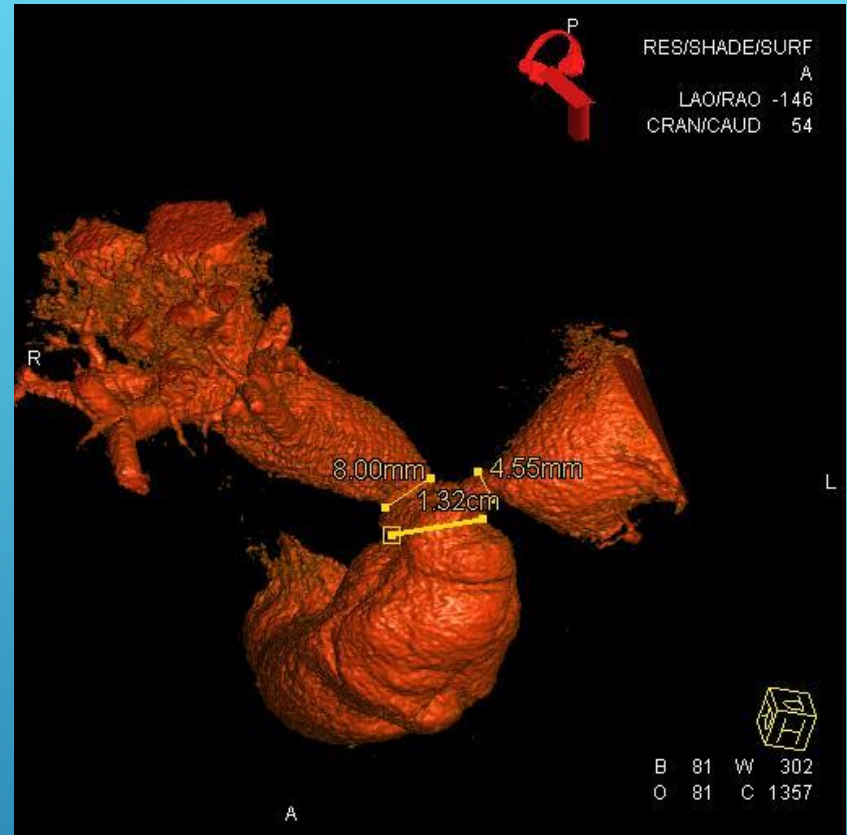
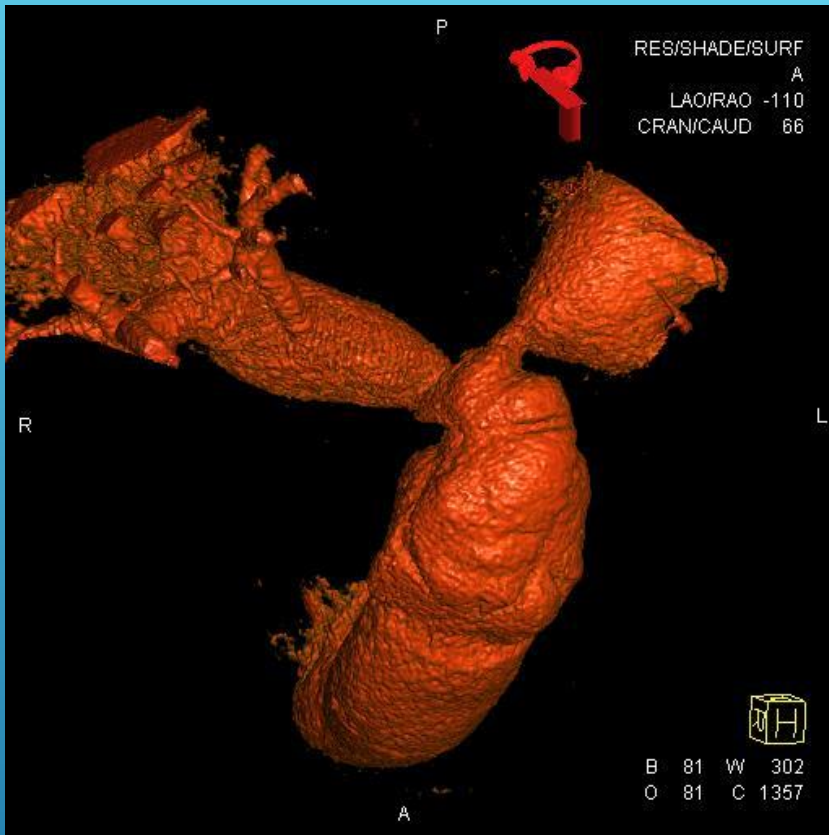




## The Congenital Heart Collaborative

University Hospitals  
Rainbow Babies & Children's  
Nationwide Children's Hospital



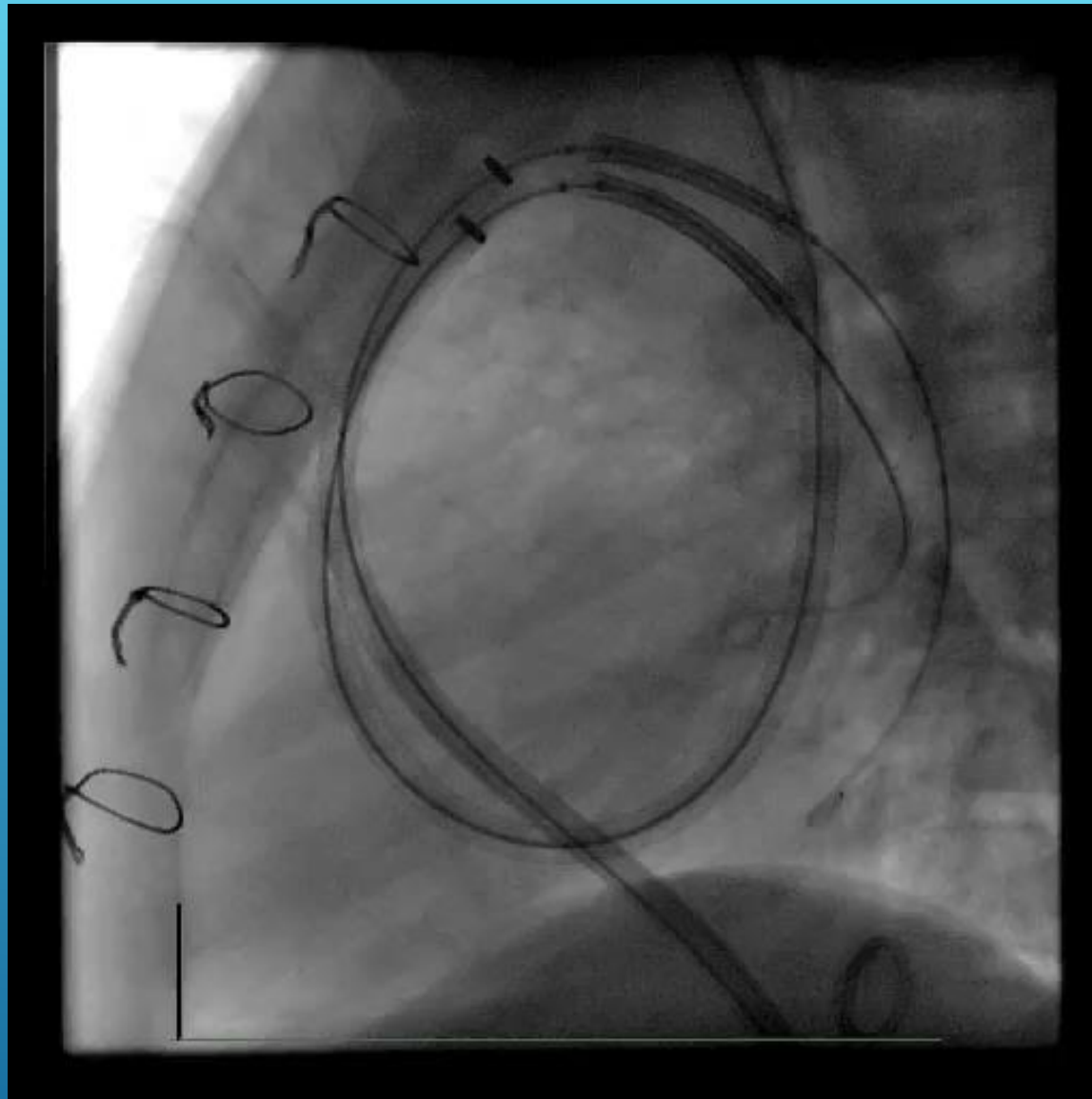


# 8 Y.O. GIRL WITH TRUNCUS ARTERIOSUS DISTAL CONDUIT & B/L BRANCH PS MILD PI



The Congenital Heart Collaborative | University Hospitals  
Rainbow Babies & Children's  
Nationwide Children's Hospital



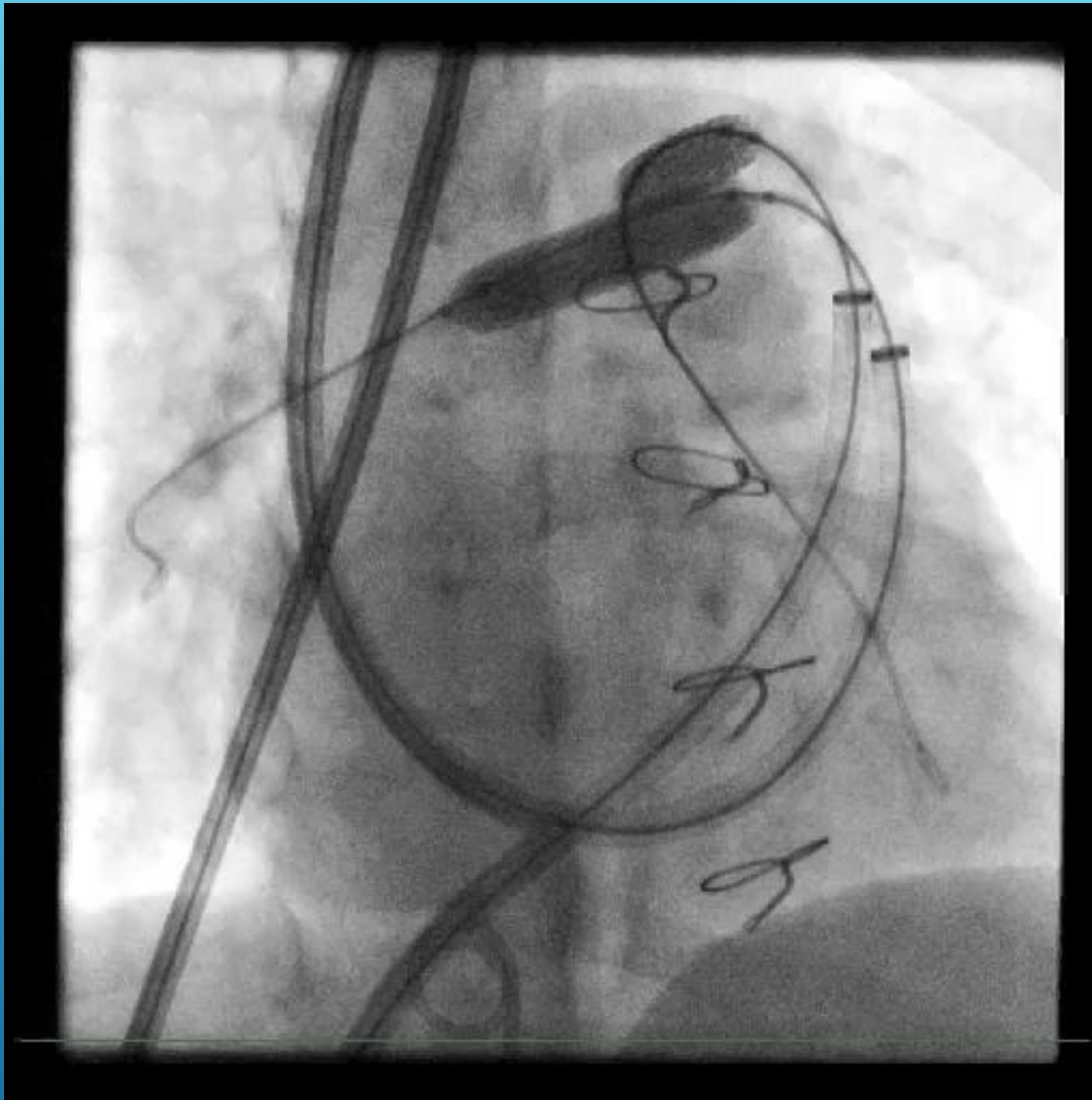


## The Congenital Heart Collaborative

University Hospitals  
Rainbow Babies & Children's  
Nationwide Children's Hospital



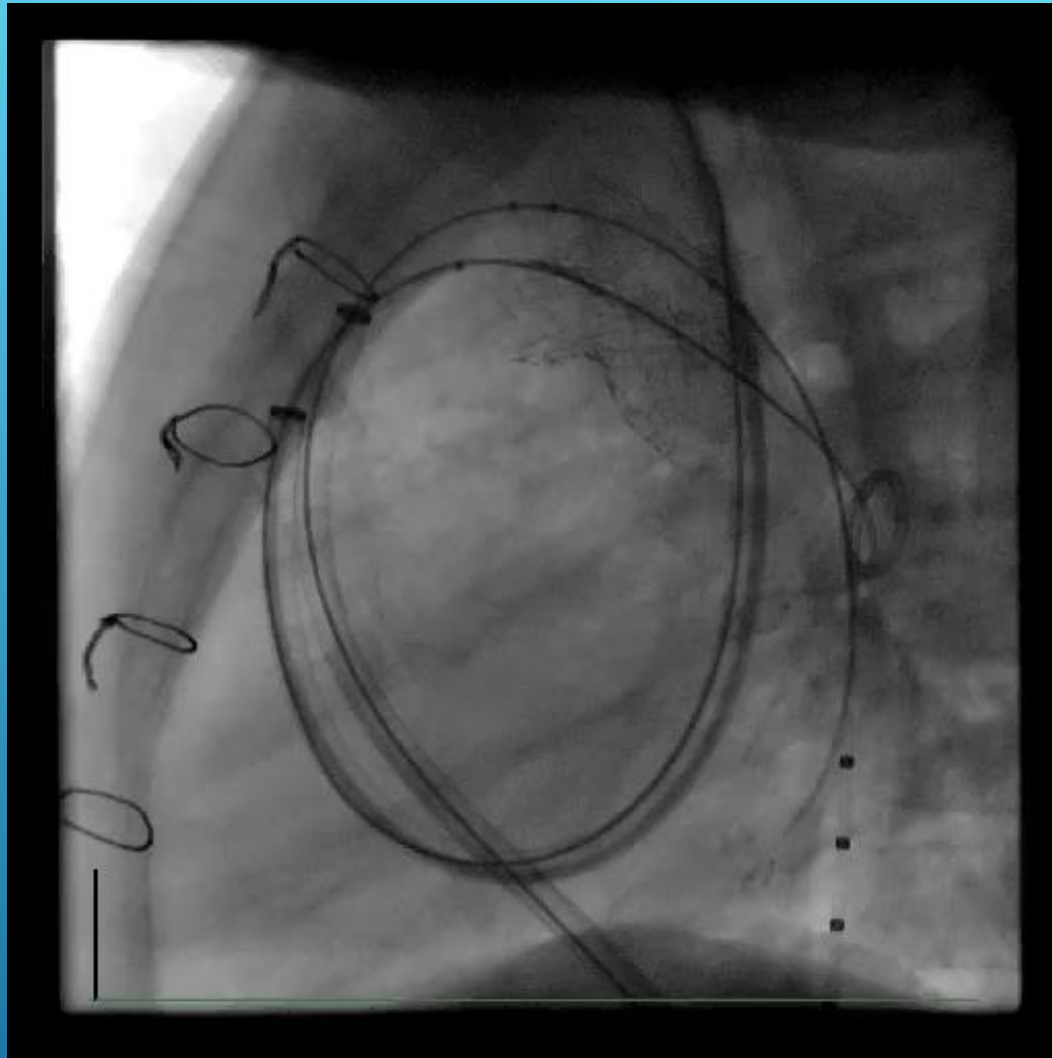




## The Congenital Heart Collaborative

University Hospitals  
Rainbow Babies & Children's  
Nationwide Children's Hospital

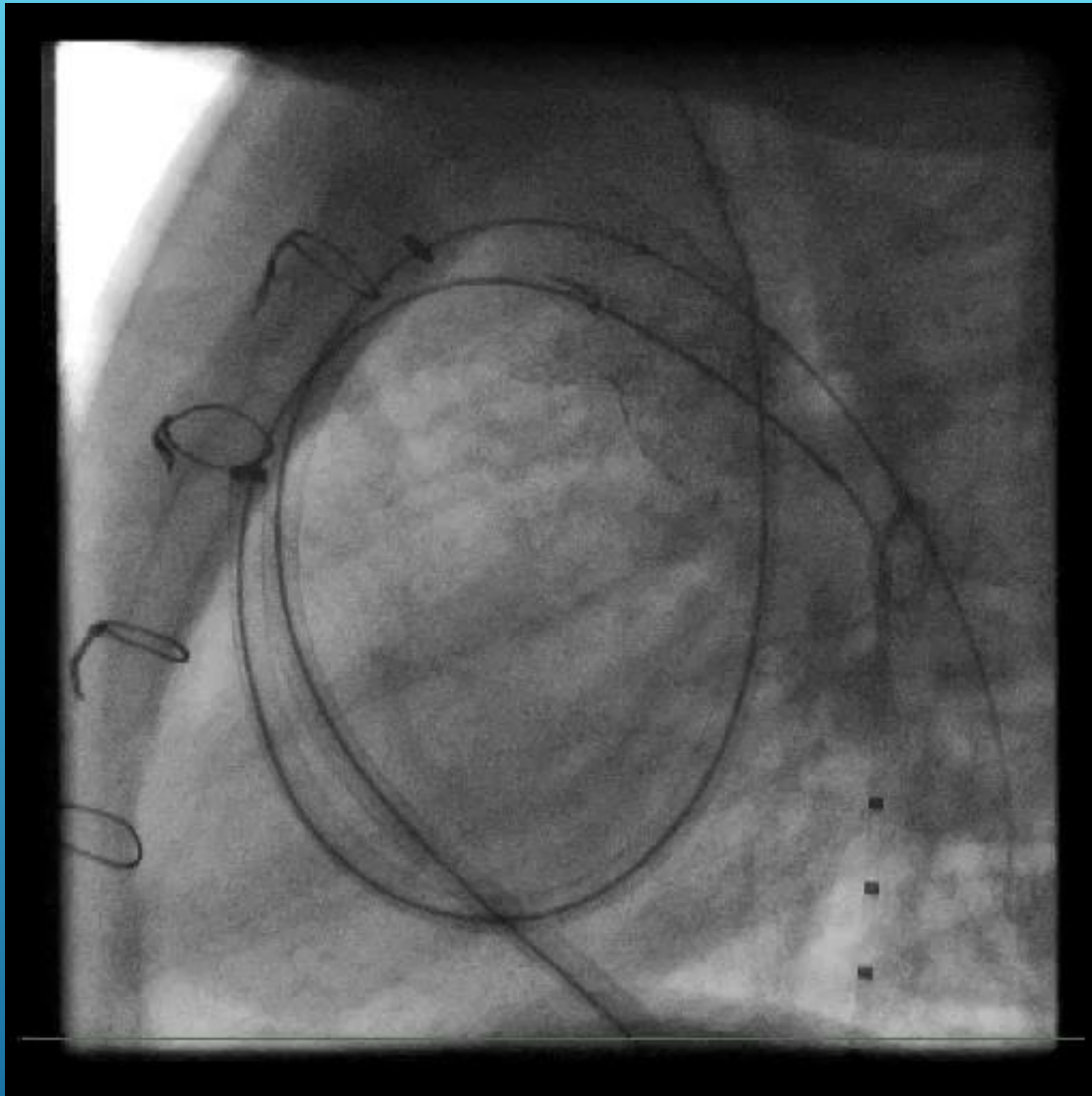




## The Congenital Heart Collaborative

University Hospitals  
Rainbow Babies & Children's  
Nationwide Children's Hospital



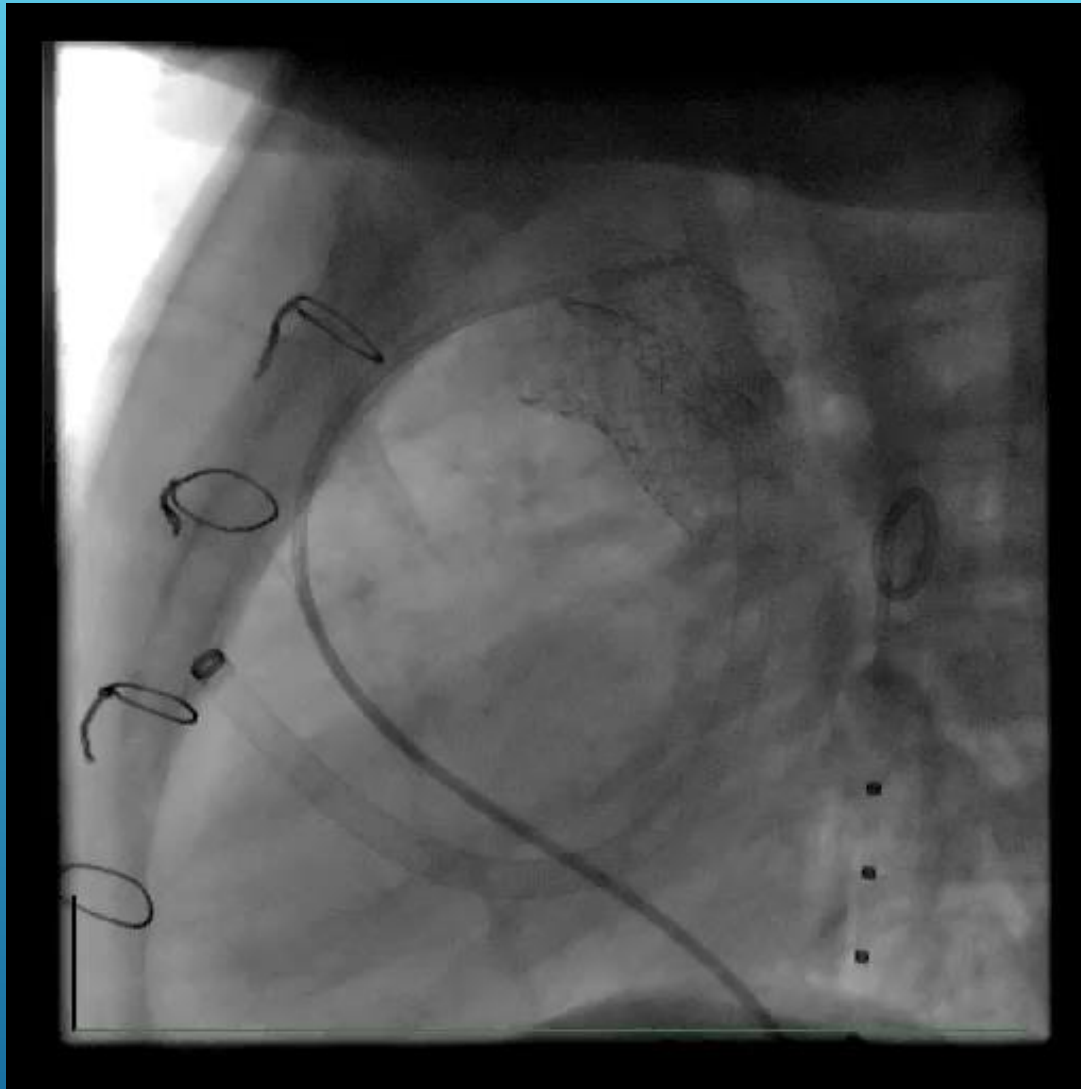


## The Congenital Heart Collaborative

University Hospitals  
Rainbow Babies & Children's  
Nationwide Children's Hospital



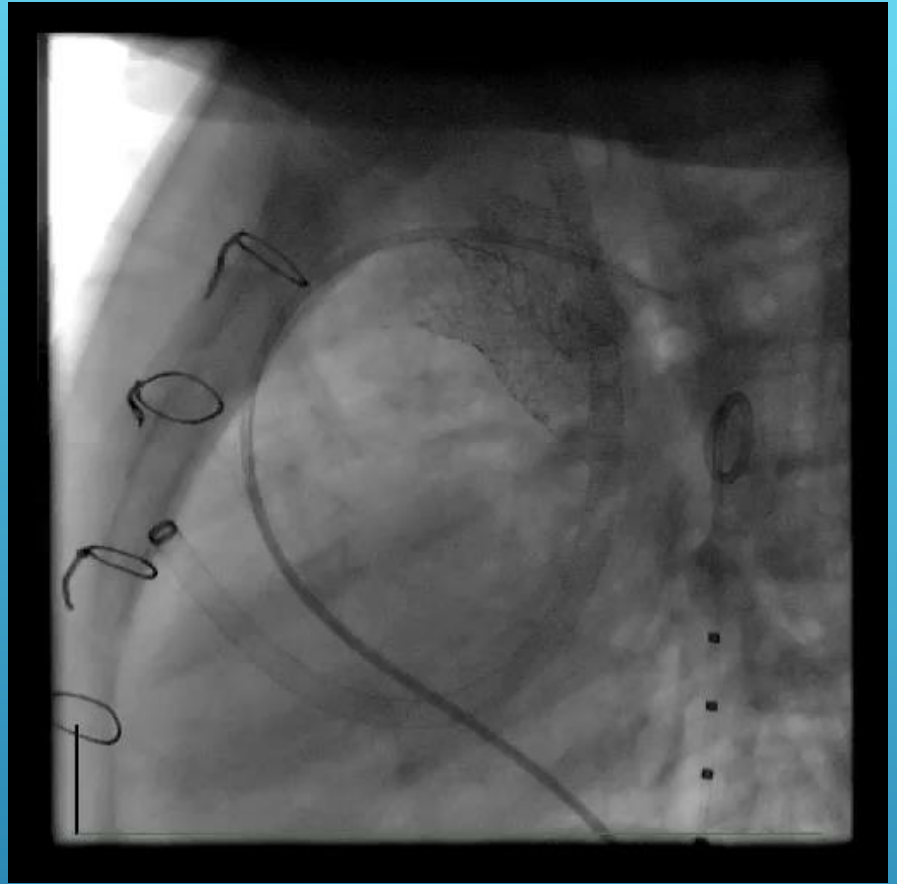
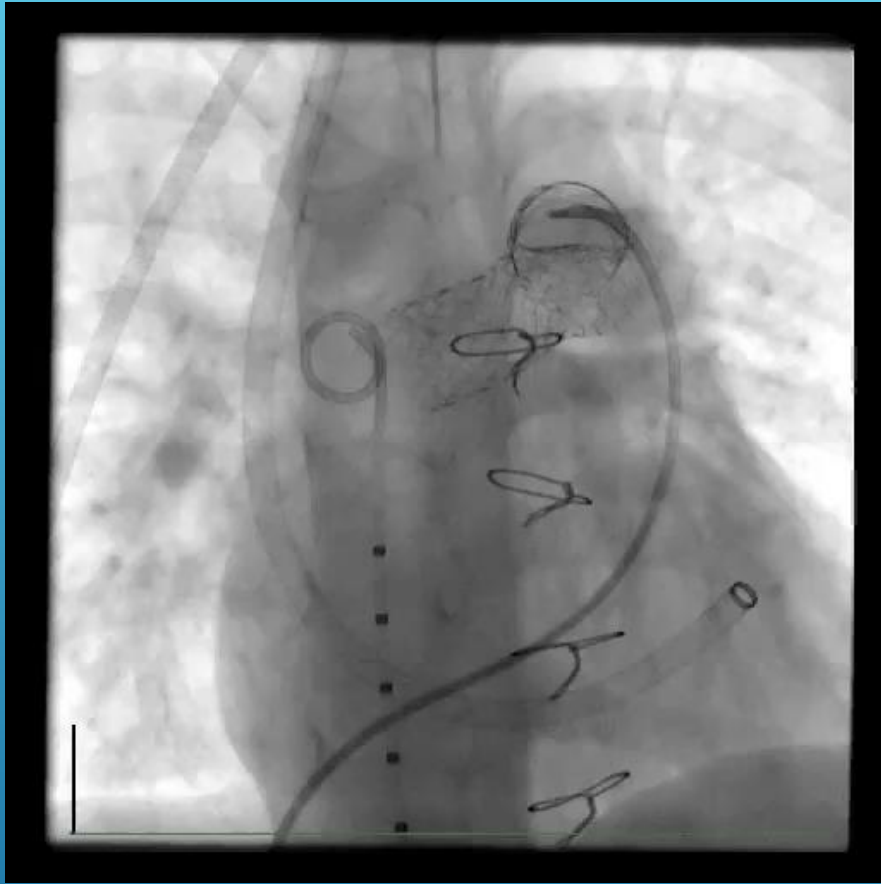




## The Congenital Heart Collaborative

University Hospitals  
Rainbow Babies & Children's  
Nationwide Children's Hospital

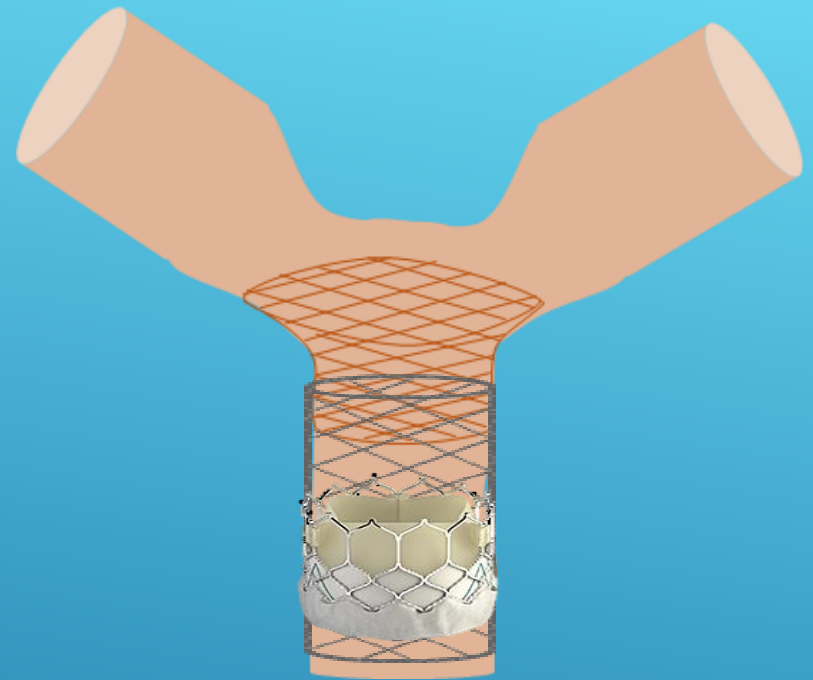
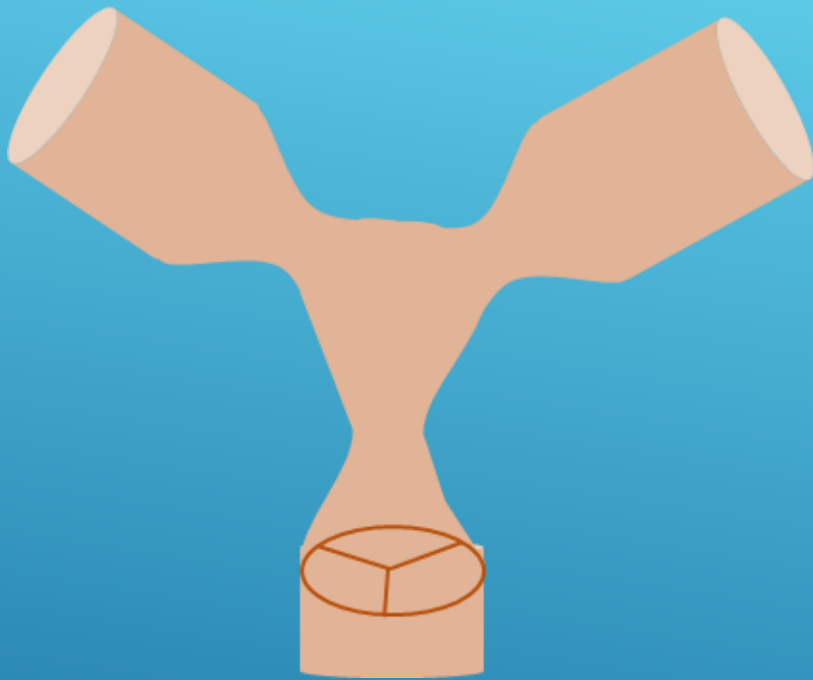




## The Congenital Heart Collaborative

University Hospitals  
Rainbow Babies & Children's  
Nationwide Children's Hospital





# STENOSIS CLOSE TO VALVE/SHORT CONDUIT BILATERAL BRANCH PS



**The Congenital Heart Collaborative** | University Hospitals  
Rainbow Babies & Children's  
Nationwide Children's Hospital

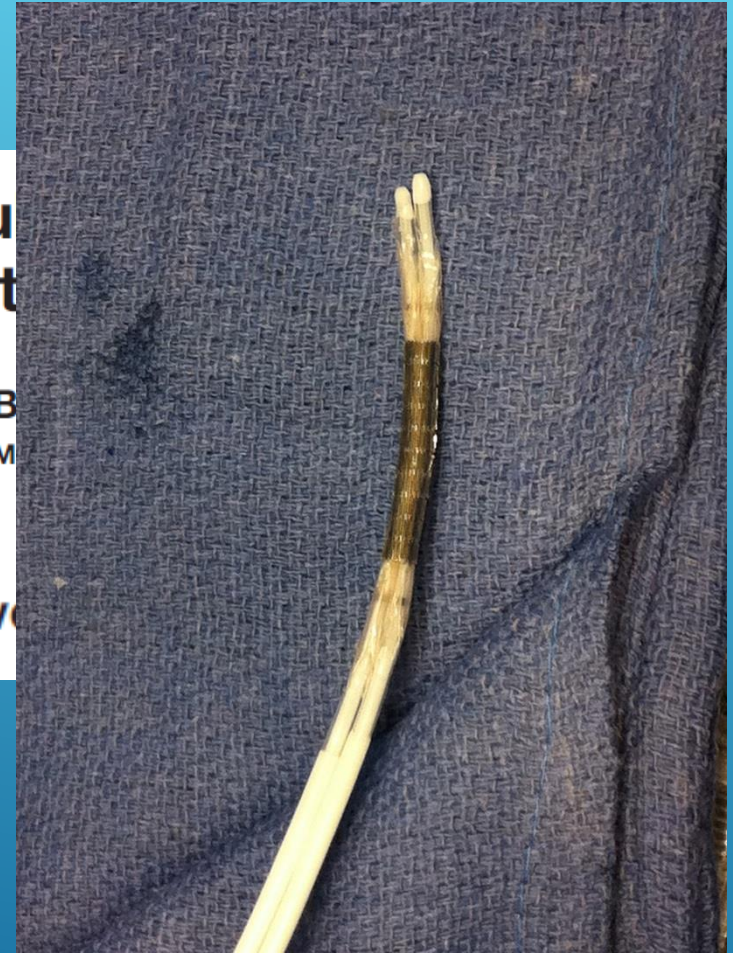


# FLOWERING STENT TECHNIQUE

## A Novel Technique for Stenting Pulmonary Conduit Bifurcation Stenosis

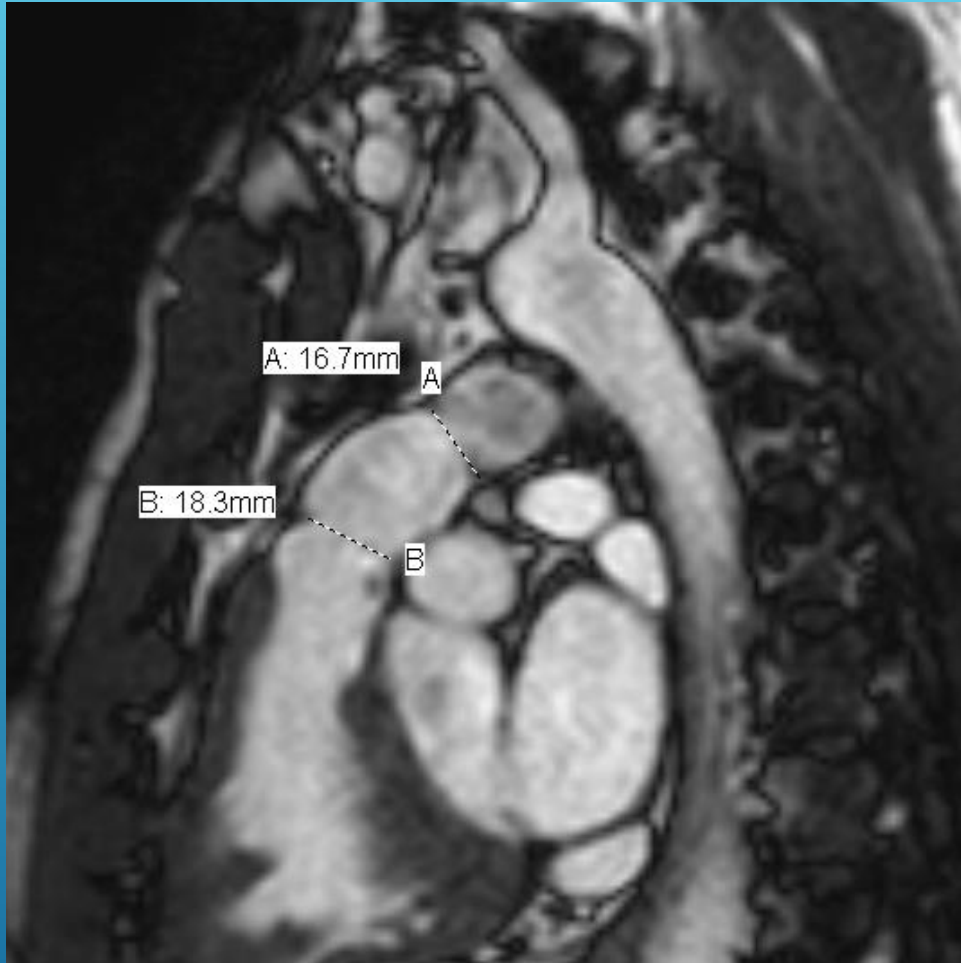
Oliver Stumper,<sup>\*</sup> MD, PhD, Vinay Bhole, MD, MRCPCH, BSc  
Zdenka Reinhardt, MD, Patrick Noonan, MD, MRCP  
Chetan Mehta, MD, MRCP

Catheterization and Cardiovascular Interventions



The Congenital Heart Collaborative | University Hospitals  
Rainbow Babies & Children's  
Nationwide Children's Hospital





42 YEAR OLD S/P ROSS  
WITH 26MM  
PULMONARY  
HOMOGRAFT

Moderate PS and  
severe PI

Proximal and distal  
conduit narrowing

Mild RPA stenosis



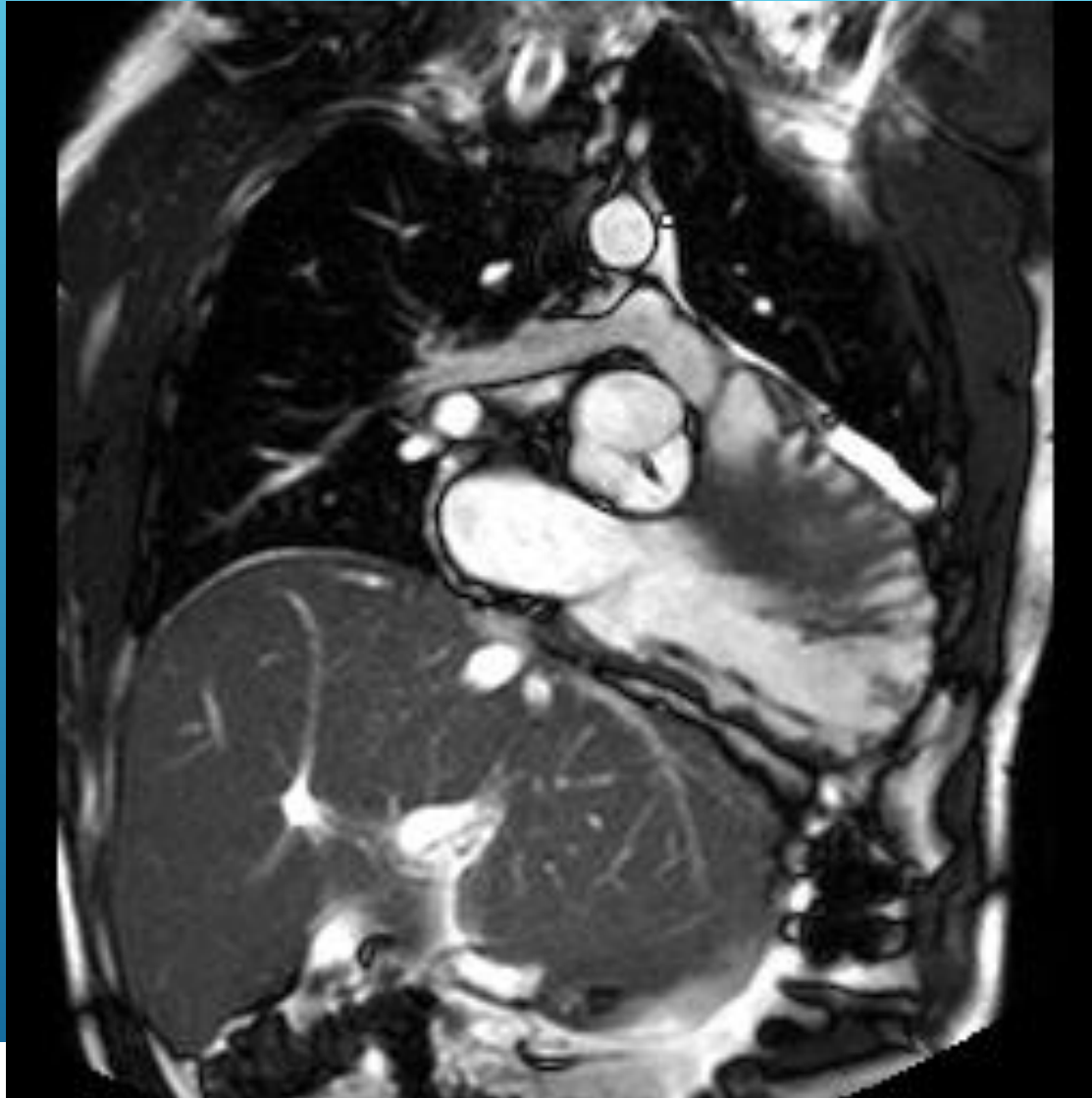The Congenital  
Heart Collaborative

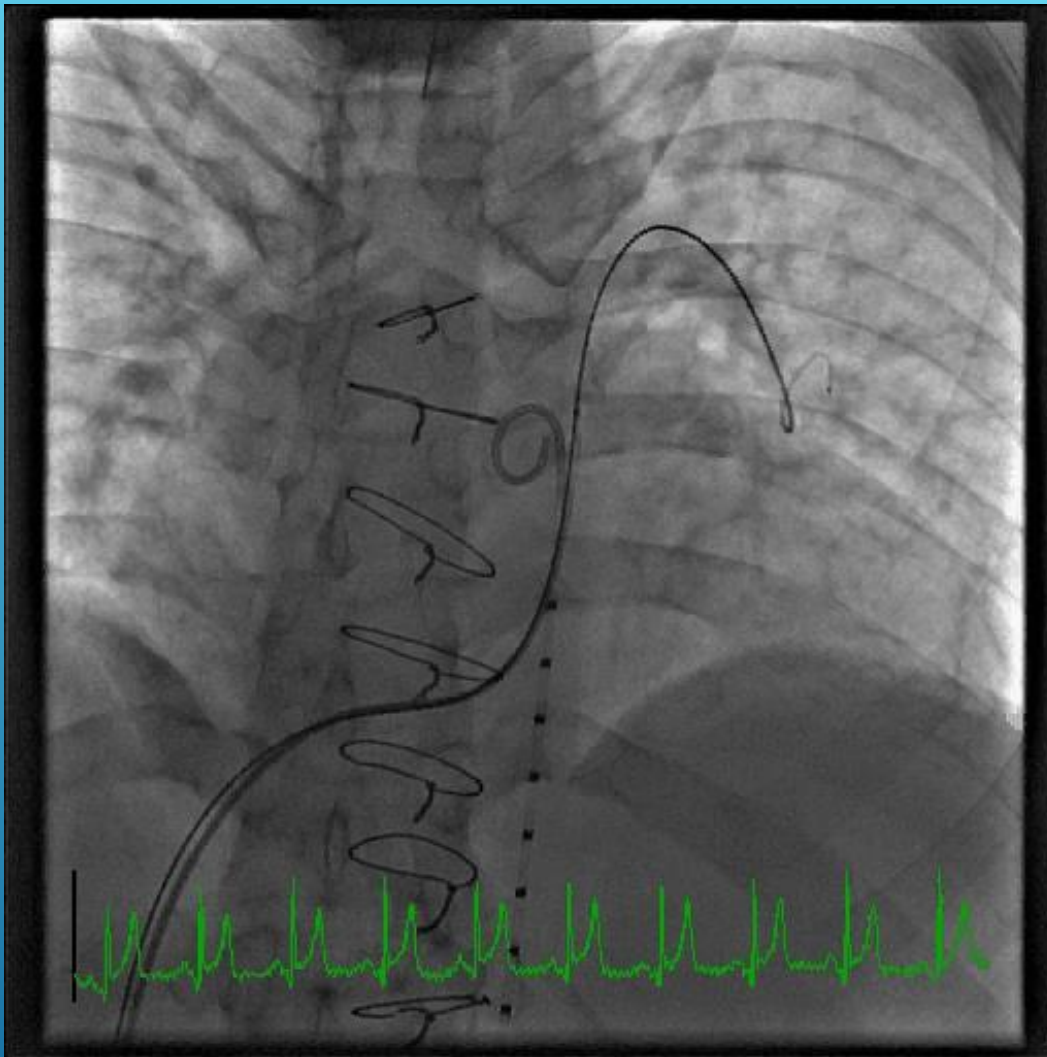
University Hospitals  
Rainbow Babies & Children's  
Nationwide Children's Hospital





# MILD RPA STENOSIS

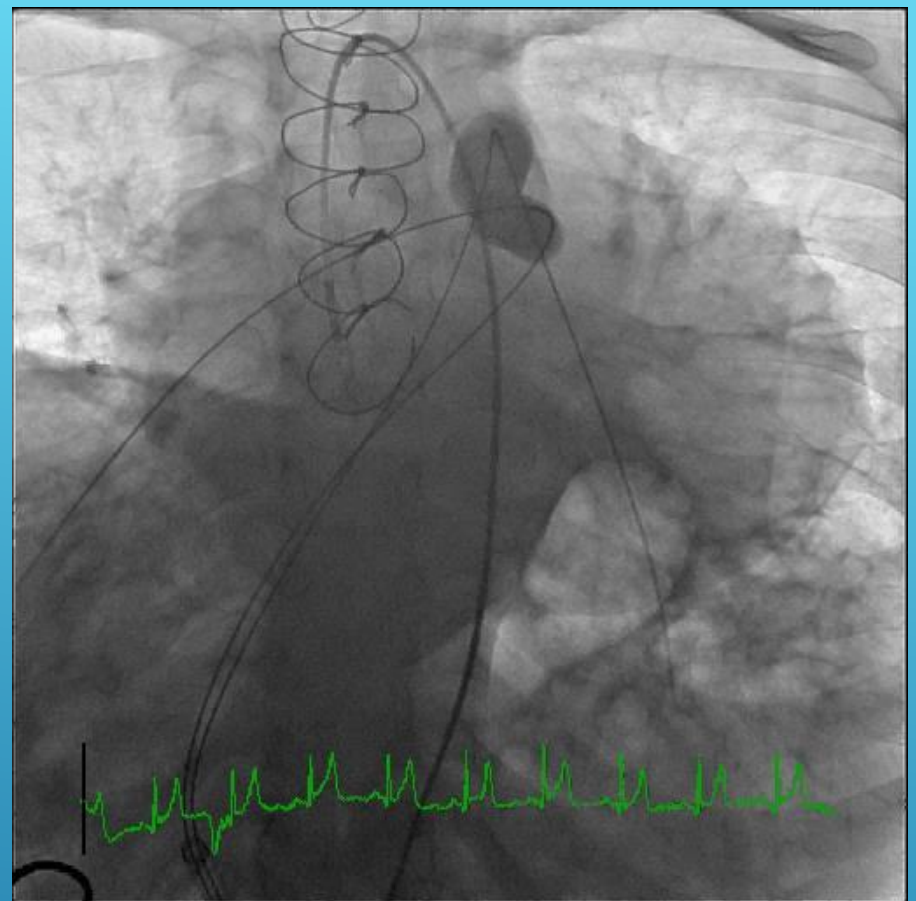
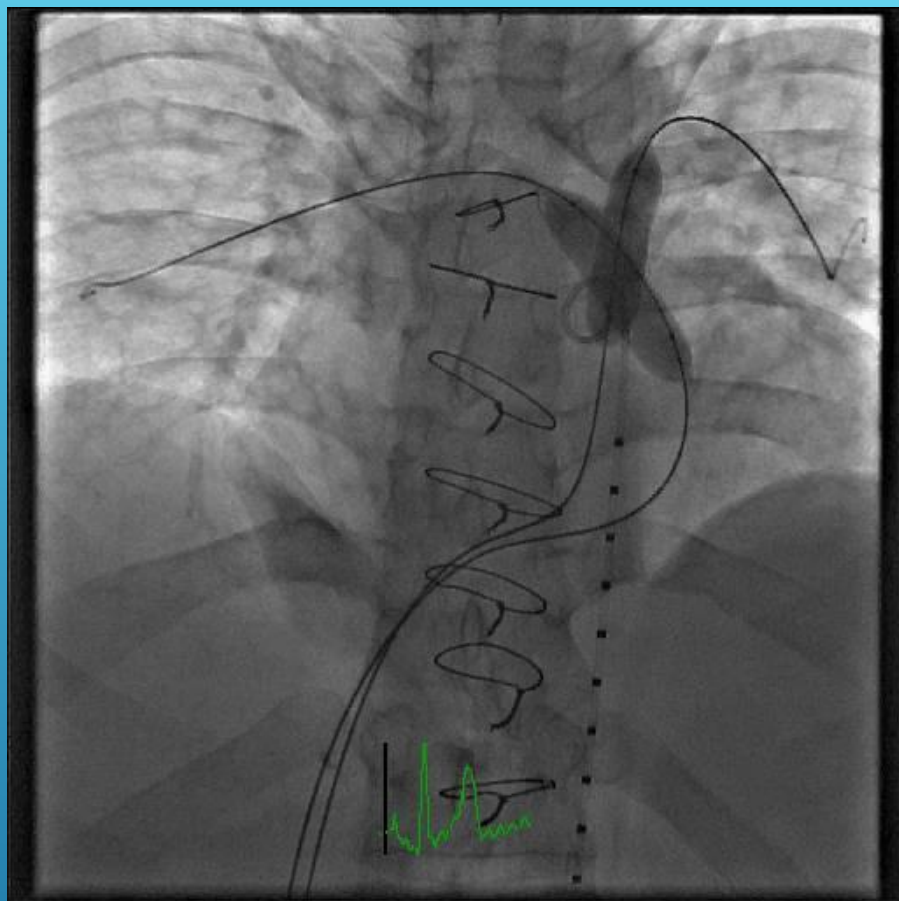




**The Congenital Heart Collaborative** | University Hospitals  
Rainbow Babies & Children's  
Nationwide Children's Hospital



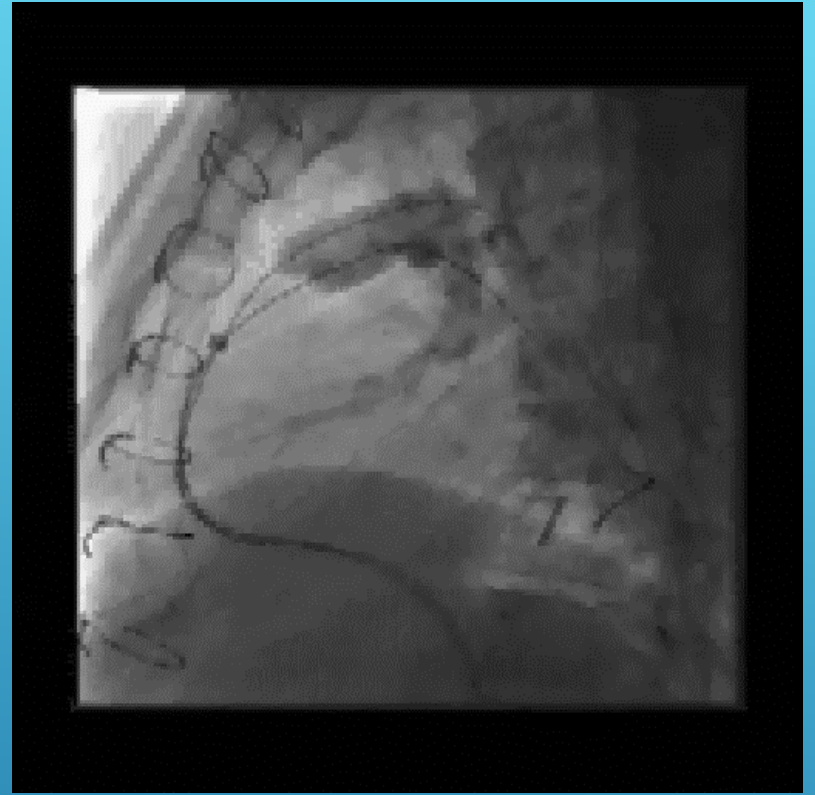
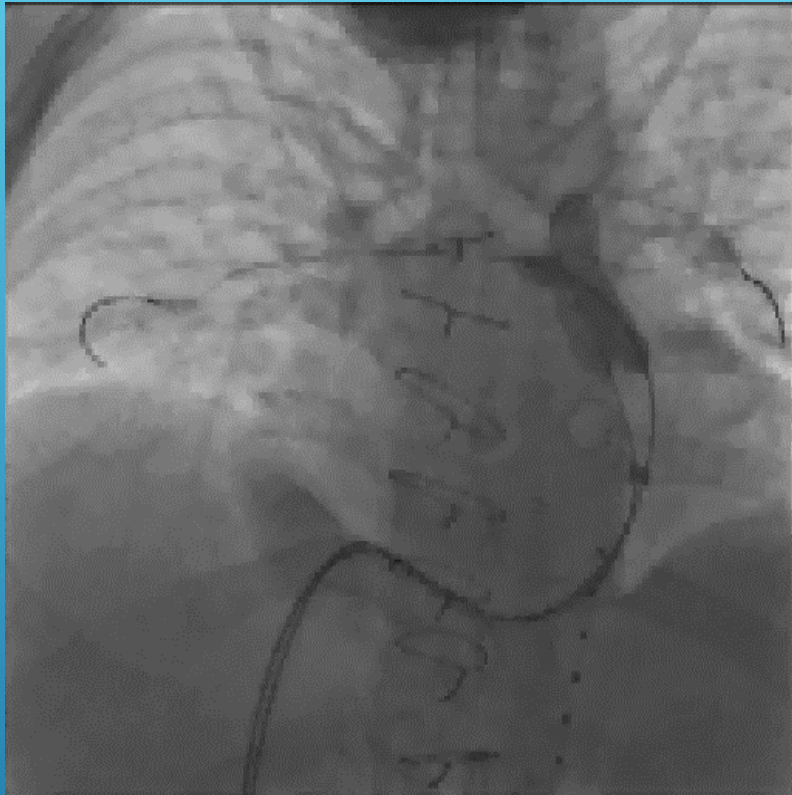




## The Congenital Heart Collaborative

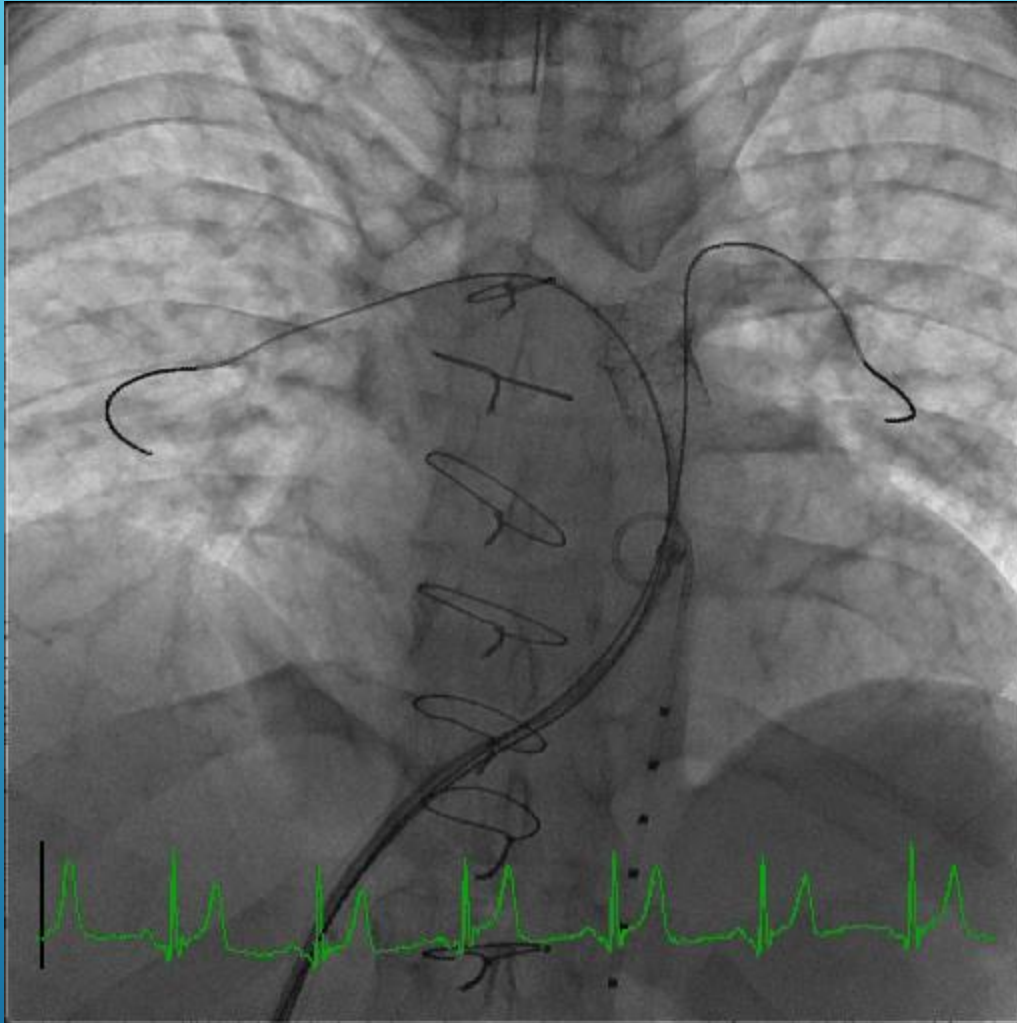
University Hospitals  
Rainbow Babies & Children's  
Nationwide Children's Hospital





**The Congenital Heart Collaborative** | University Hospitals  
Rainbow Babies & Children's  
Nationwide Children's Hospital



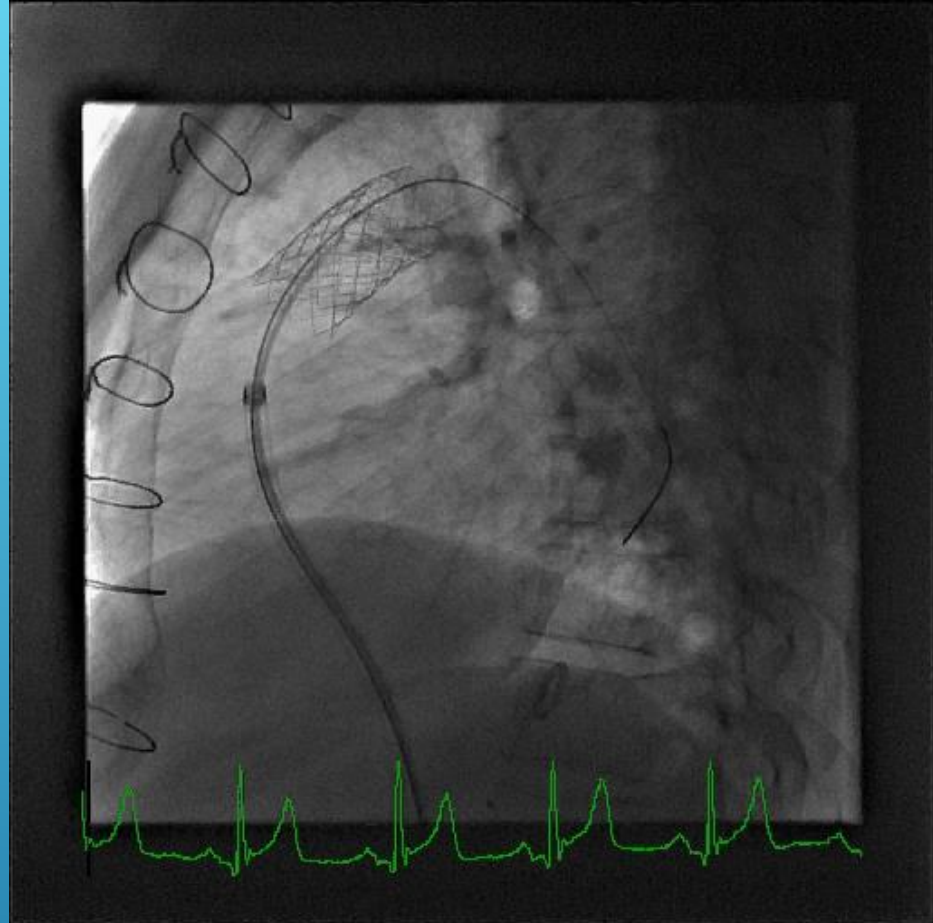
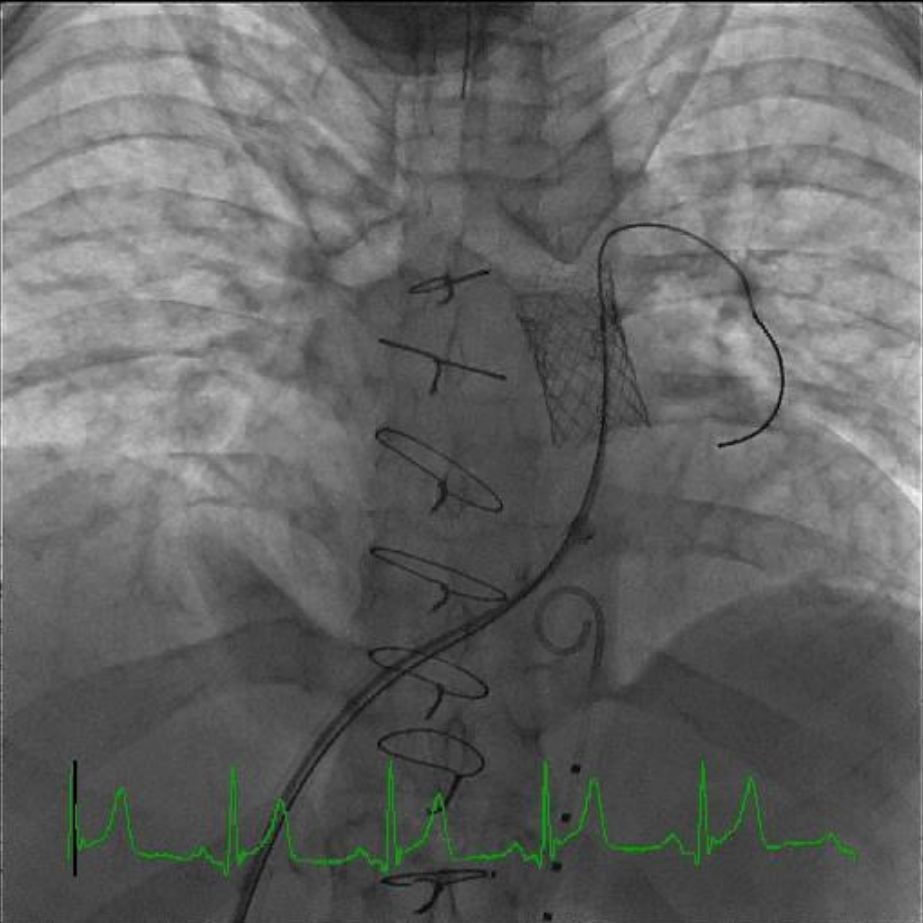


## The Congenital Heart Collaborative

University Hospitals  
Rainbow Babies & Children's  
Nationwide Children's Hospital

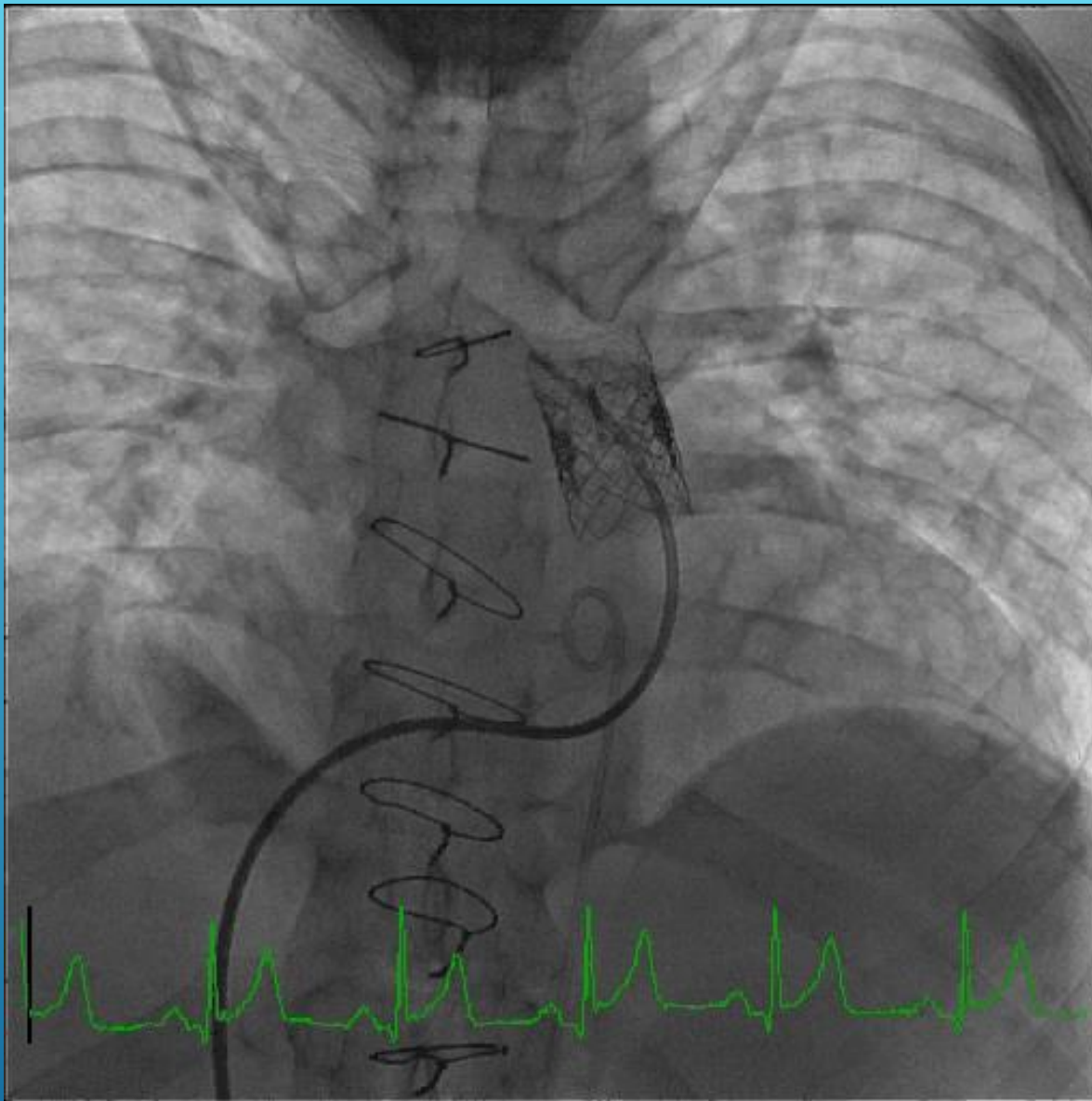






**The Congenital Heart Collaborative** | University Hospitals  
Rainbow Babies & Children's  
Nationwide Children's Hospital

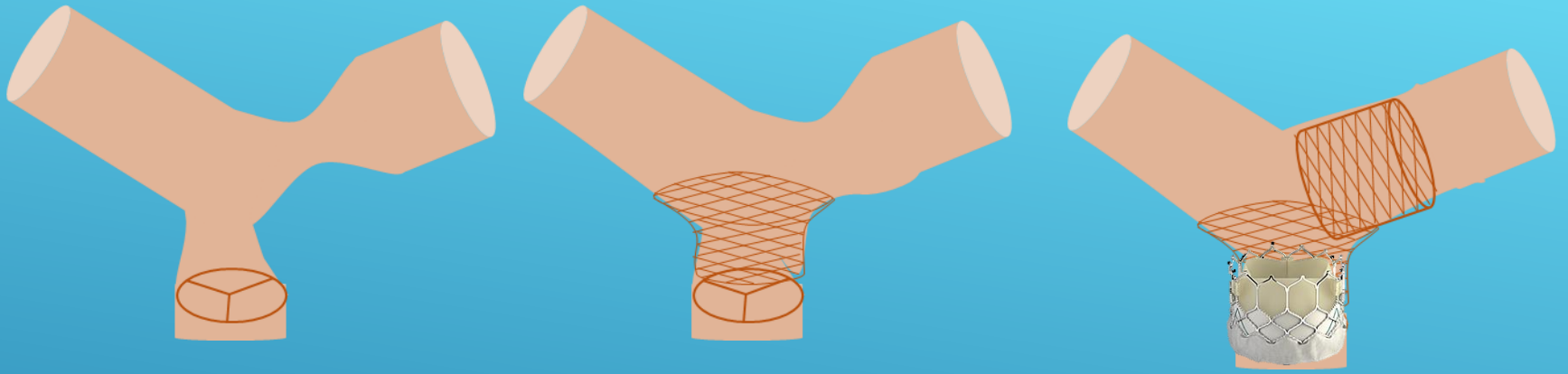




## The Congenital Heart Collaborative

University Hospitals  
Rainbow Babies & Children's  
Nationwide Children's Hospital





# STENOSIS CLOSE TO VALVE/SHORT CONDUIT UNILATERAL BRANCH PS



**The Congenital Heart Collaborative** | University Hospitals  
Rainbow Babies & Children's  
Nationwide Children's Hospital



- ▶ 6 y/o male DORV, Pulmonary atresia
  - ▶ Neonatal right-sided mBTS (7/2005)
  - ▶ Rastelli repair, 12mm aortic homograft (12/2005)
  - ▶ Recurrent conduit stenosis
    - ▶ bare metal stenting (2006 – 2009)
  - ▶ Surgical RV-PA conduit replacement (3/2011)
    - ▶ 20mm Contegra® graft



**The Congenital Heart Collaborative** | University Hospitals  
Rainbow Babies & Children's  
Nationwide Children's Hospital





S

P

P

S

R

R

R

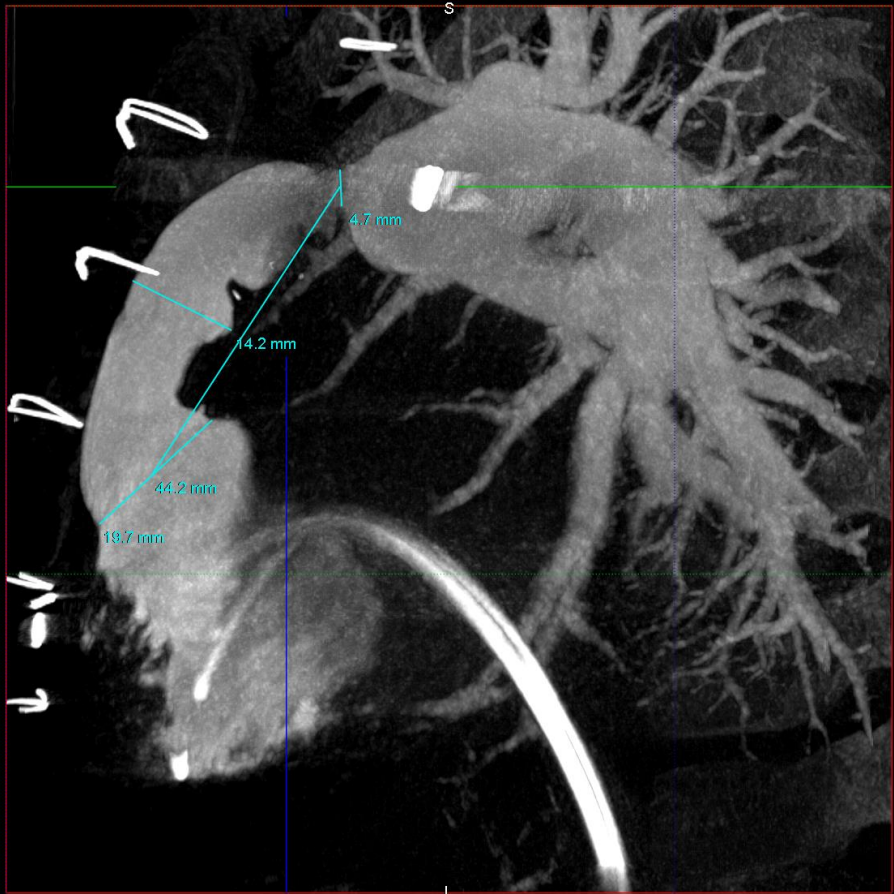A

P

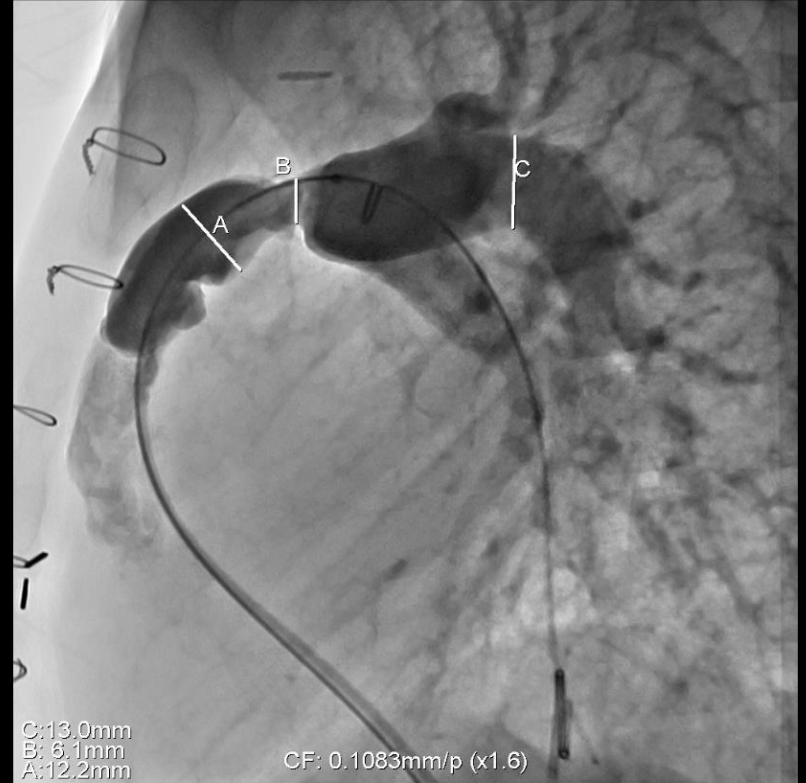
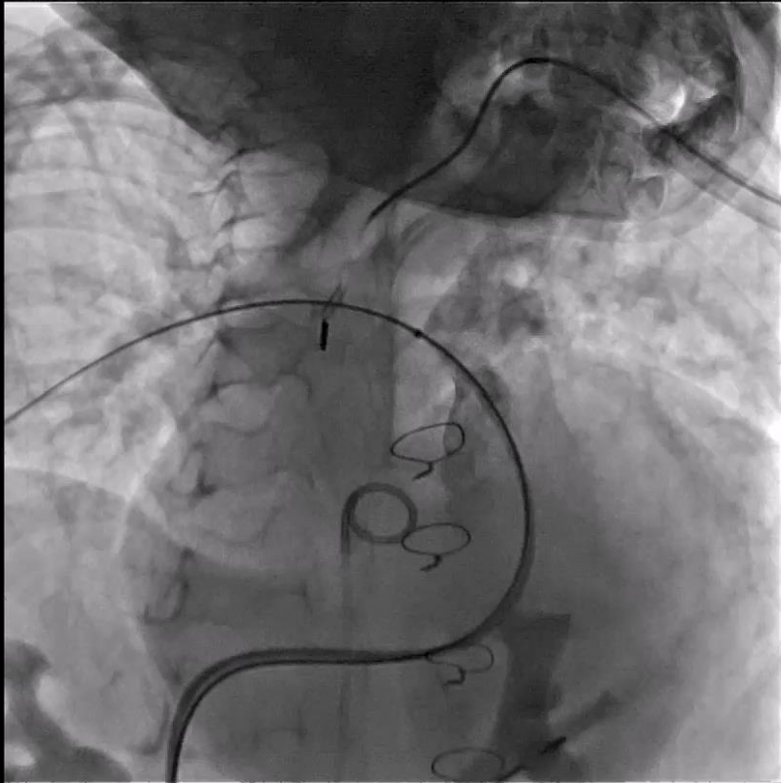
LA00 CRA0

RA033 CRA6

5 cm



Lossy Compression - not intended for diagnosis

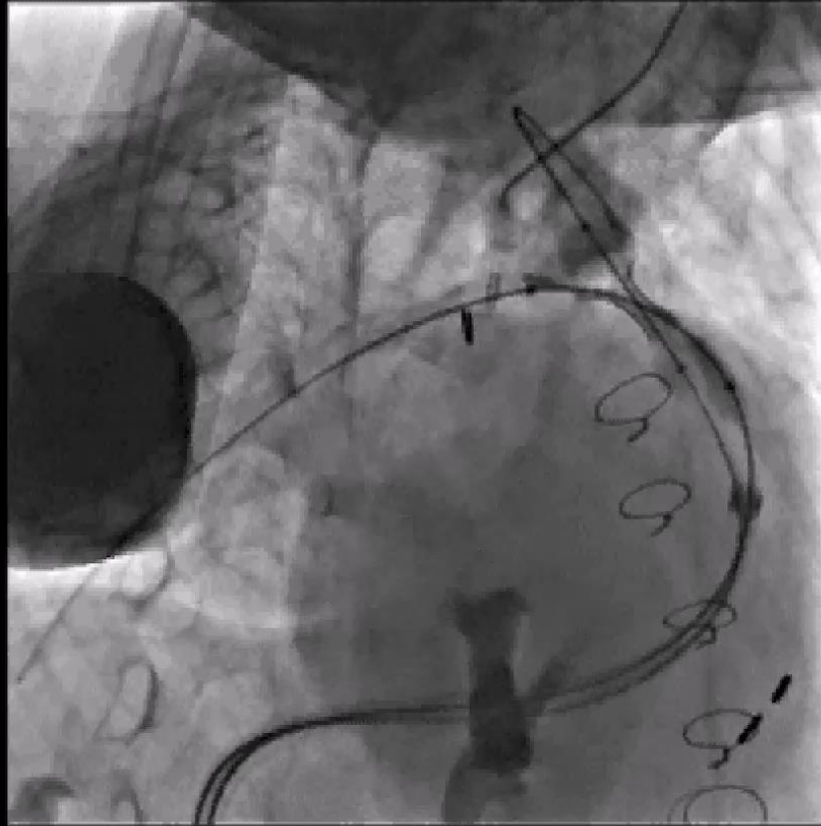


The Congenital Heart Collaborative

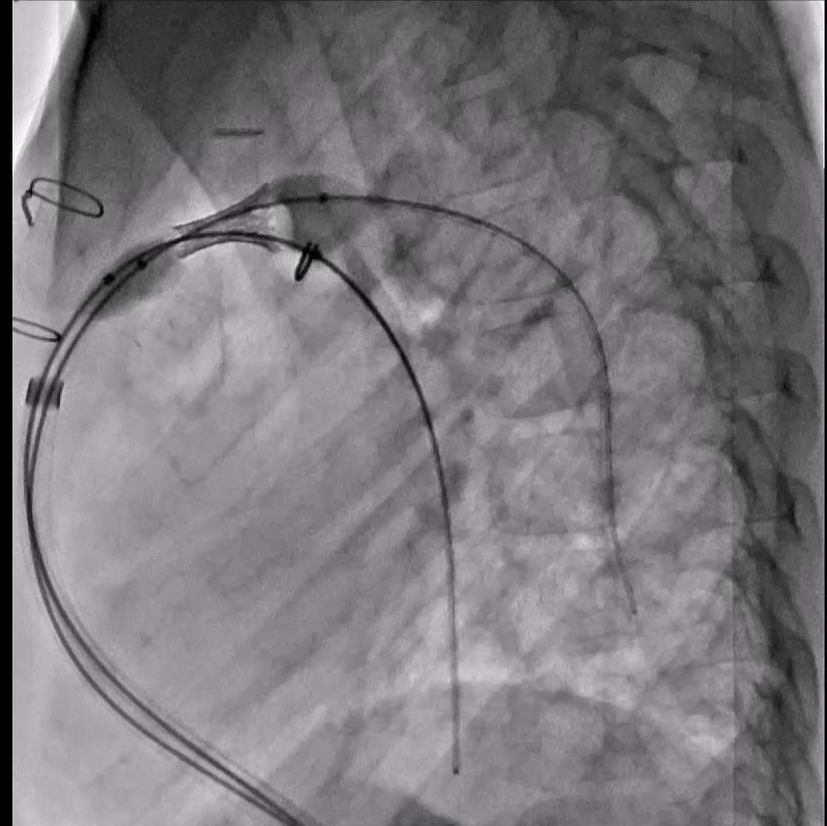
University Hospitals  
Rainbow Babies & Children's  
Nationwide Children's Hospital



Lossy Compression - not intended for diagnosis

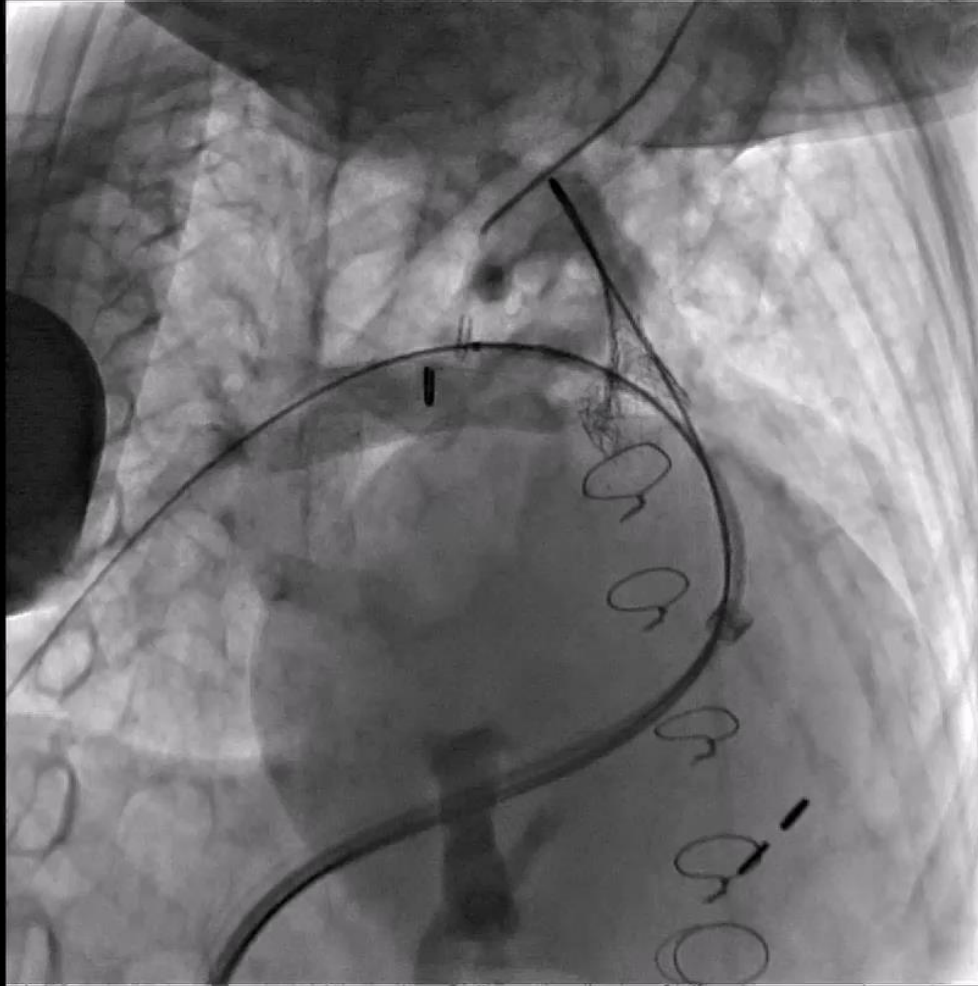


Lossy Compression - not intended for diagnosis



# RPA ANGIOGRAM POST-STENT

Lossy Compression - not intended for diagnosis

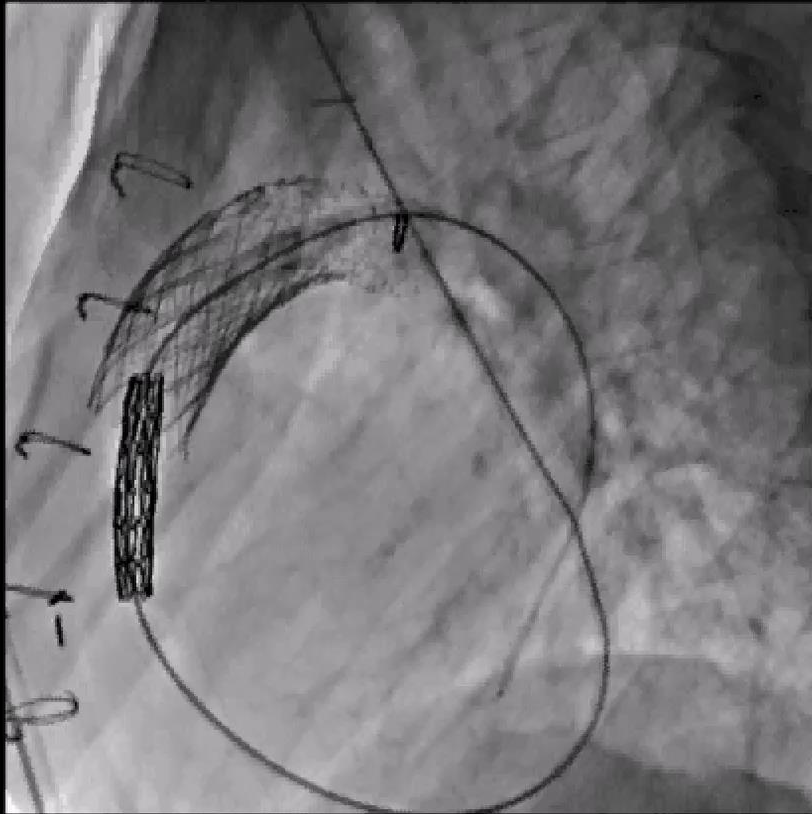


**Congenital Heart Collaborative** | University Hospitals  
Rainbow Babies & Children's  
Nationwide Children's Hospital

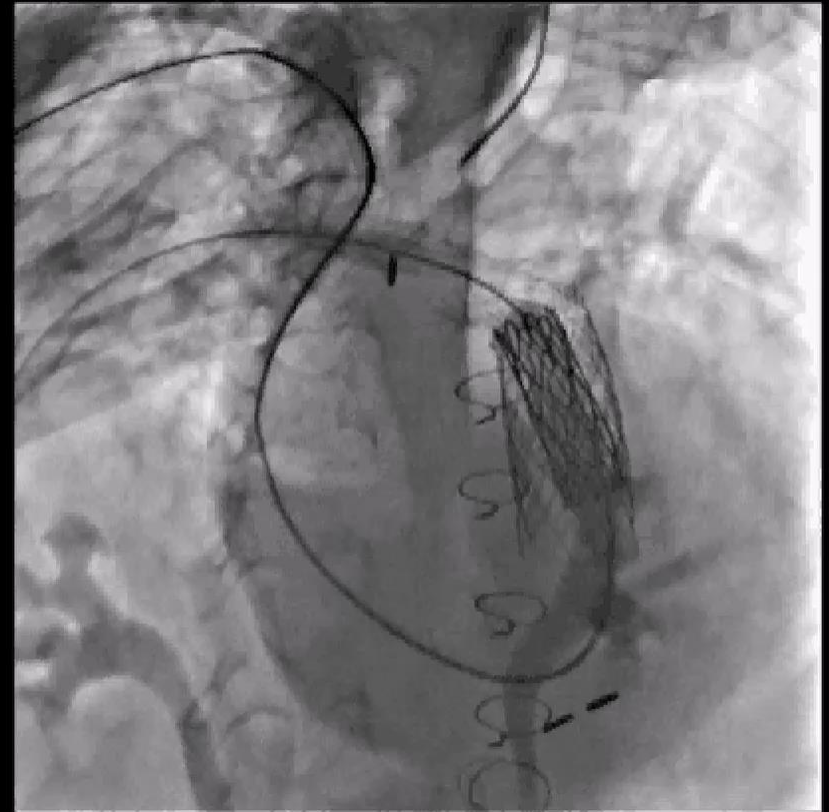



Loopy Compression - not intended for diagnosis



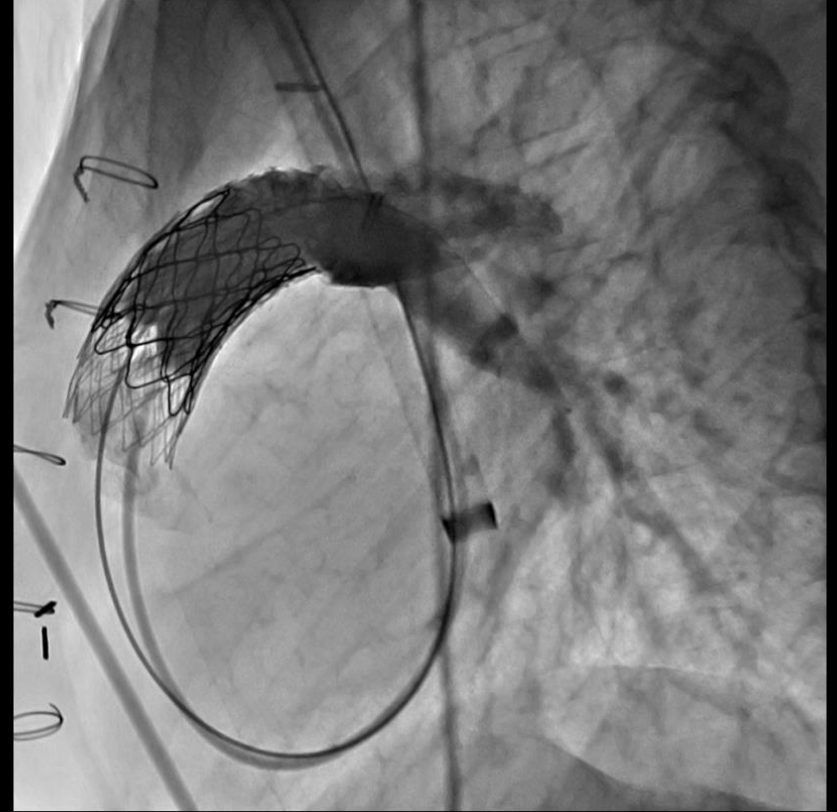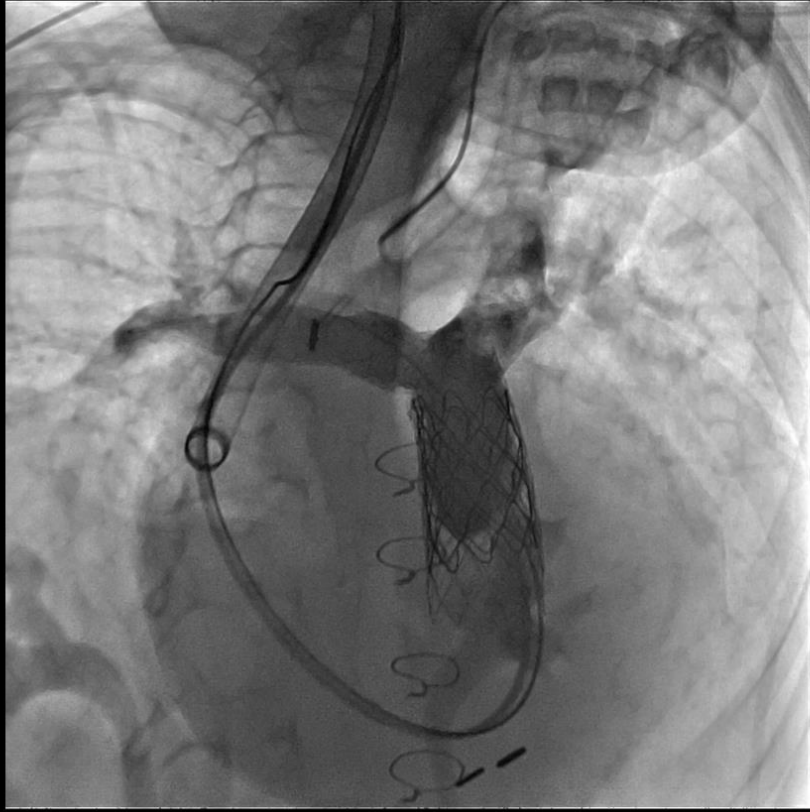
Loopy Compression - not intended for diagnosis



The Congenital  
Heart Collaborative

Rainbow Babies & Children's  
Nationwide Children's Hospital





**The Congenital Heart Collaborative** | University Hospitals  
Rainbow Babies & Children's  
Nationwide Children's Hospital



THIS IS THE END



**The Congenital Heart Collaborative** | University Hospitals  
Rainbow Babies & Children's  
Nationwide Children's Hospital

