

Stenting the Transverse Aortic Arch



Darren P. Berman, MD

Co-Director, Cardiac Catheterization and Interventional Therapies

Nationwide Children's Hospital

The Heart Center

Assistant Professor, Pediatrics

The Ohio State University



NATIONWIDE CHILDREN'S
When your child needs a hospital, everything matters.™

Objectives

- What we know about transverse arch hypoplasia
- Case example
- What we know about stenting the transverse aortic arch (TAA)
 - Published data
 - Our preliminary data



Coarctation, tubular hypoplasia, and the ductus arteriosus

Histological study of 35 specimens¹

S. YEN HO AND ROBERT H. ANDERSON

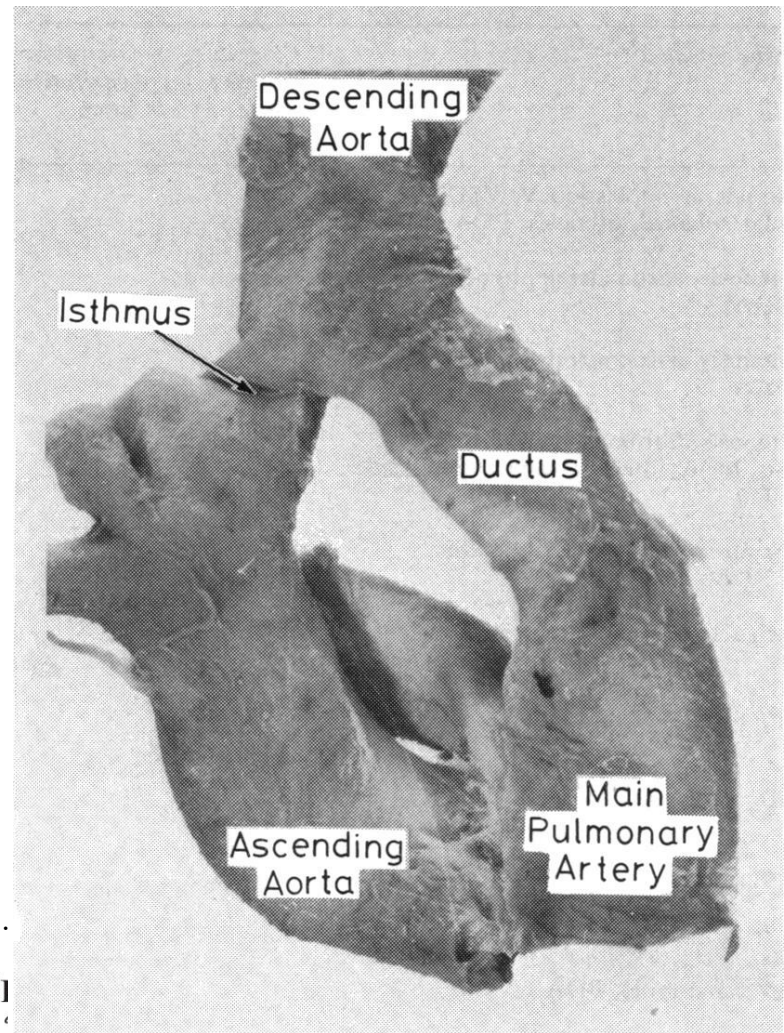
From the Department of Paediatric Cardiac Morphology, Cardiothoracic Institute, Brompton Hospital, London

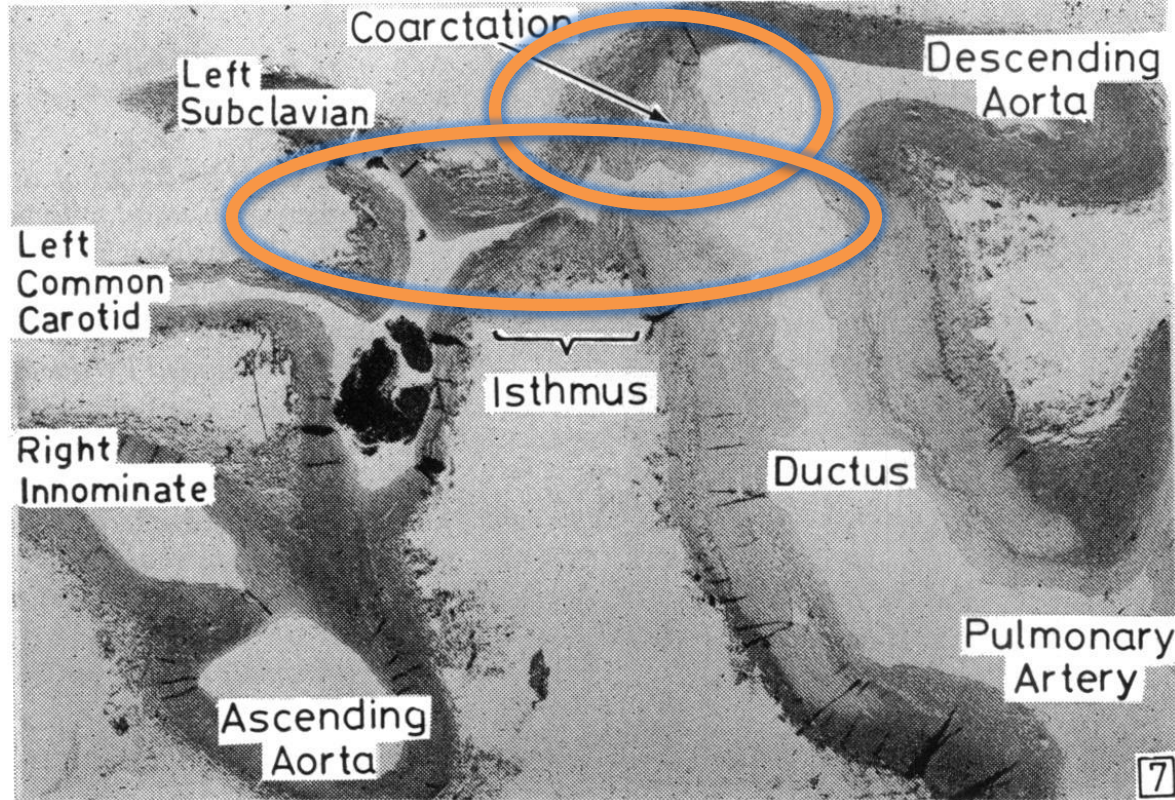
- Pathologic study
- Further define the relationship between the ductus arteriosus, coarctation, and tubular hypoplasia of the aortic arch
- Thirty-five aortic arch systems



- Normal newborn aortic arch
- The isthmus is slightly narrower than either the ascending or descending aorta

Ho SY, Anderson RH. Coarctation, tubular hypoplasia, and the ductus arteriosus. *BHJ*, 1979, 41, 268-274.





Ho SY, Anderson RH. Coarctation, tubular hypoplasia, and the ductus arteriosus. *BHJ*, 1979, 41, 268-274.

Coarctation of the Aorta: The Heart Center Following Successful Treatment

- 30% of patients have important systemic HTN
- Contributes to cardiovascular morbidity and mortality
 - high incidence of coronary artery disease and stroke
- Why this high prevalence of HTN?
 - Residual arch obstruction
 - Abnormal aortic arch shape
 - Abnormal vascular properties of the systemic vasculature

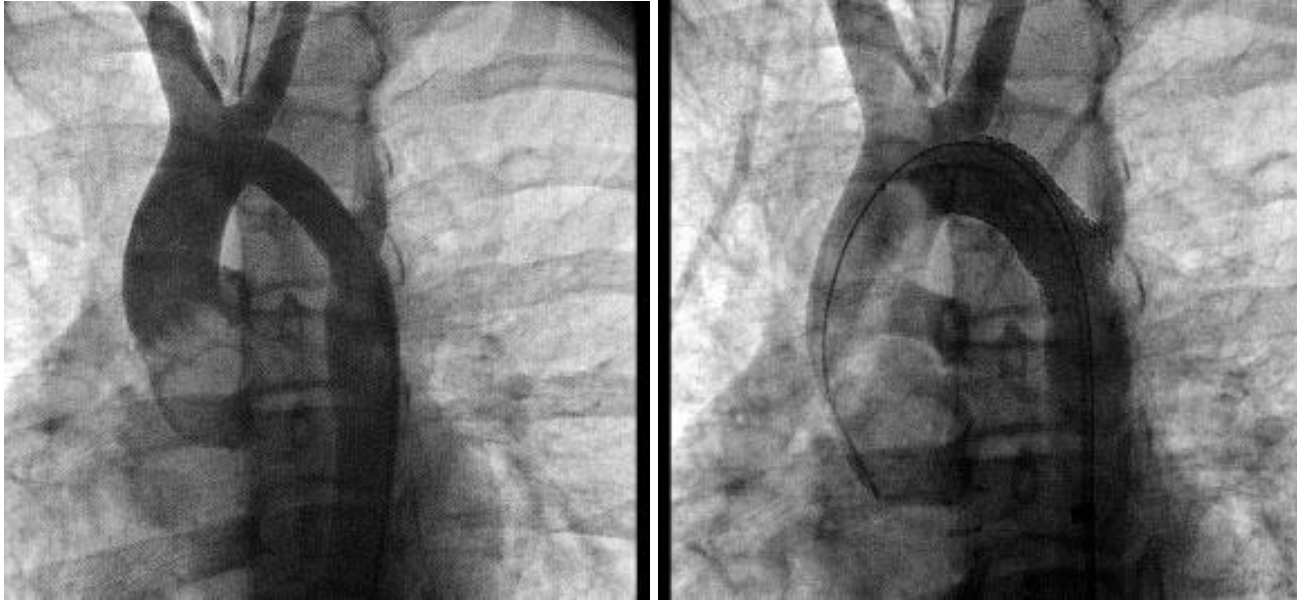O'Sullivan J. Late hypertension in patients with repaired aortic coarctation. *Curr Hypertens Rep.* 2014;16:421.

Cohen M, Fuster V, Steele PM, Driscoll D, McGoon DC. Coarctation of the aorta. Long-term follow-up and prediction of outcome after surgical correction. *Circulation.* 1989;80:840-845.



NATIONWIDE CHILDREN'S
When your child needs a hospital, everything matters.™

Does Transverse Aortic Arch Hypoplasia contribute to this systemic HTN?



Persistent Aortic Arch Hypoplasia After Coarctation Treatment Is Associated With Late Systemic Hypertension

Sophie Quennelle; Andrew J. Powell, MD; Tal Geva, MD; Ashwin Prakash, MD

Background—Mild transverse aortic arch (TAA) hypoplasia is common after coarctation treatment, but is considered benign in the absence of an arm-leg systolic blood pressure (SBP) difference. Hypertension (HTN) is a common long-term morbidity after successful coarctation treatment. We examined whether mild TAA hypoplasia after coarctation treatment is associated with late systemic HTN.

Methods and Results—We retrospectively reviewed 92 patients (median age, 19.9 years; range, 4.9 to 57.8; 60% male) 14.1±10.3 years after successful coarctation treatment (surgery in 63, stent in 16, and balloon dilation in 13), excluding those with resting right arm-leg blood pressure gradient >20 mm Hg, atypical coarctation, and major associated heart defects. Minimum body-surface area (BSA)-adjusted TAA cross-sectional area (CSA) was calculated from cardiac magnetic resonance (CMR) images. On follow-up, 38 of 92 (41%) patients had systemic HTN using standard criteria. Systemic HTN was independently associated with smaller TAA CSA/BSA ($P=0.006$; odds ratio [OR], 6.41 per 0.5 cm²/m² decrease), higher age at CMR ($P=0.03$; OR, 1.57 per 5-year increase), and in a subset ($n=61$), higher arm-leg SBP difference during exercise ($P=0.05$; OR, 1.03 per 1-mm-Hg increase). Lower ratio of TAA diameter/descending aorta diameter was associated with a larger increase in right arm SBP during peak exercise ($P=0.006$; $r^2=0.11$).

Conclusions—Persistent mild aortic arch hypoplasia, even in the absence of an arm-leg SBP difference at rest, is associated with late systemic HTN. Further studies should be undertaken to determine whether more-aggressive arch reconstruction at initial repair can reduce the incidence of systemic HTN. (*J Am Heart Assoc.* 2015;4:e001978 doi: 10.1161/JAHA.115.001978)

Parameter	All Patients (n=92)	Hypertensive (n=38)	Normotensive (n=54)	P Value
Age at CMR, years	19.9 (4.9 to 57.8)	21.4 (10.2 to 57.8)	19.4 (4.9 to 49.5)	0.13
Males (%)	56 (61)	21 (58)	35 (63)	0.83
Age at initial repair, years	4.6 (0 to 57.1)	4.3 (0 to 57.1)	5.0 (0 to 38.9)	0.95
Time since repair, years	13.5 (0 to 48.2)	13.9 (0 to 48.2)	12.5 (1.1 to 33.5)	0.48
TAA CSA/BSA, cm ² /m ²	1.06 (0.47 to 2.2)	0.92 (0.50 to 2.20)	1.18 (0.47 to 2.0)	0.004
TAA/DAO diameter ratio	0.92 (0.43 to 1.27)	0.87 (0.43 to 1.27)	0.94 (0.67 to 1.27)	0.02
Arm-leg SBP gradient, mm Hg	-8 (-60 to 18)	-5 (-45 to 18)	-9 (-60 to 14)	0.14
Isthmus/DAO diameter ratio	0.85 (0.43 to 1.75)	0.77 (0.43 to 1.31)	0.88 (0.56 to 1.75)	0.02
Right arm SBP, mm Hg	123 (86 to 174)	129 (101 to 174)	120 (86 to 152)	0.003
Right arm DBP, mm Hg	63 (35 to 87)	63 (48 to 83)	63 (35 to 87)	0.84
Antihypertensive medication (%)	33 (36)	33 (87)	0	<0.0001
Arm-leg SBP gradient during exercise, mm Hg	33 (-39 to 120)	47 (-15 to 120)	29 (-39 to 73)	0.04
Increase in right arm SBP during exercise, mm Hg	51 (1 to 108)	64 (1 to 103)	42 (3 to 108)	0.28
Right arm hypertension during exercise, >220 mm Hg (%)	10/57 (18)	7/22 (32)	3/35 (9)	0.03

- **Persistent mild TAA hypoplasia**
- **In the absence of an arm-leg SBP difference at rest**
- **Is associated with late systemic HTN**

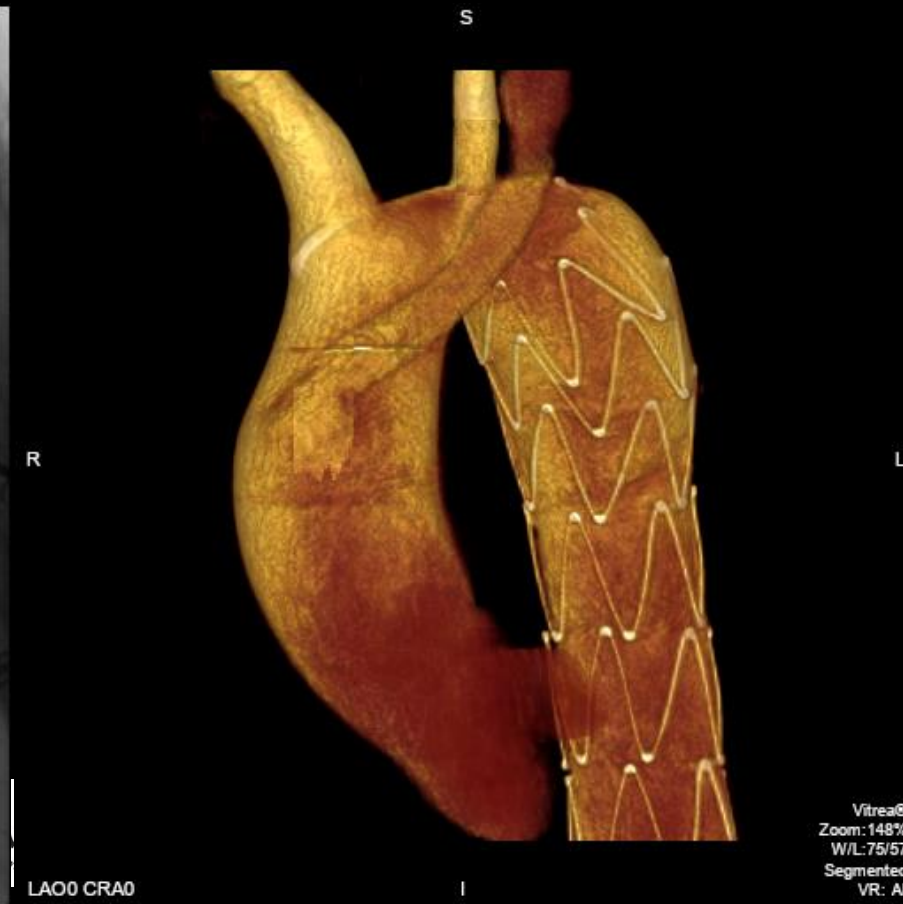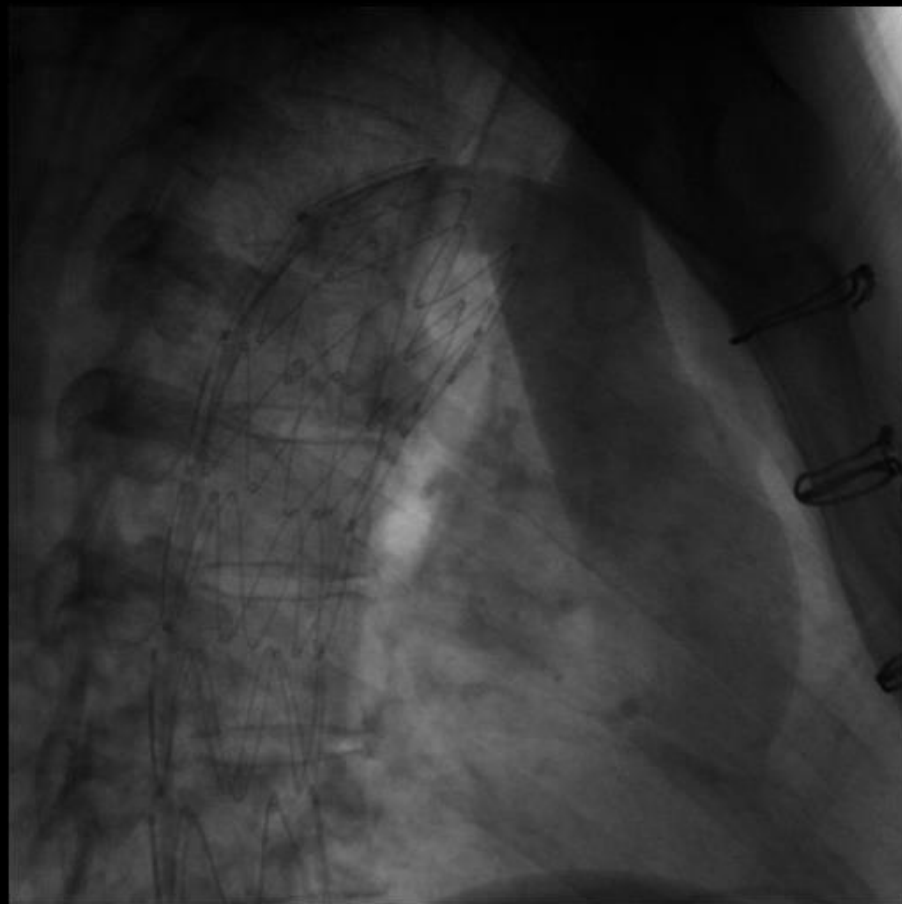
Should we be more aggressive about mild TAA hypoplasia?

Case Example

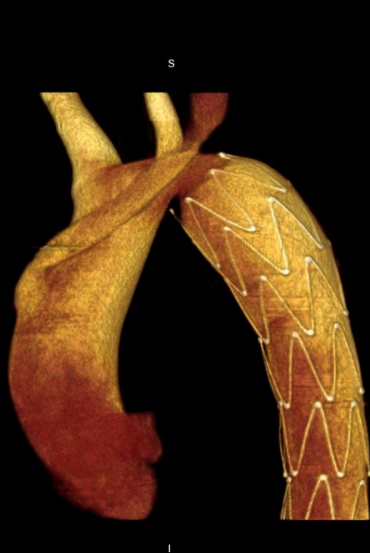- 46 y/o female born with Coarctation of aorta
- Surgical repair in 1981 (14y/o)
- Aortic aneurysm (timing unclear)
- Endovascular graft placement
 - Reimplantation of LSCA onto ascending aorta
- Now with transverse aortic arch hypoplasia/stenosis



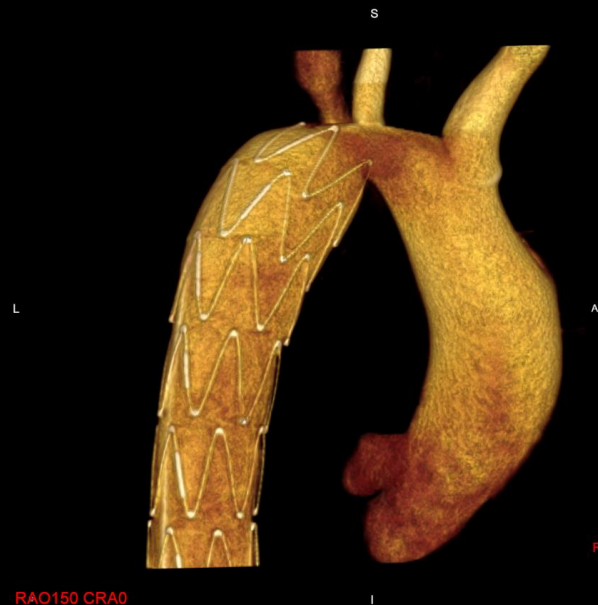3DRA AAO; RRVP at 180/min



The Heart Center

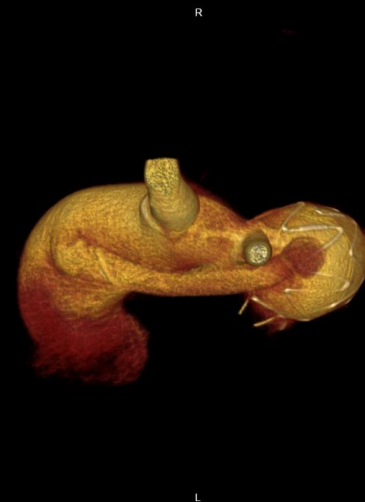

LAO54 CRA0

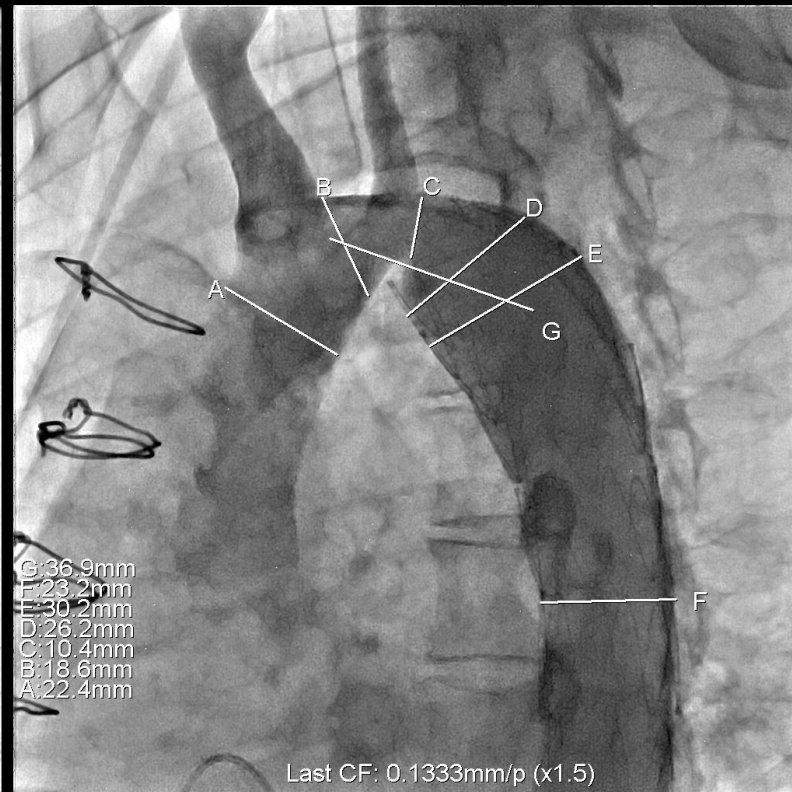
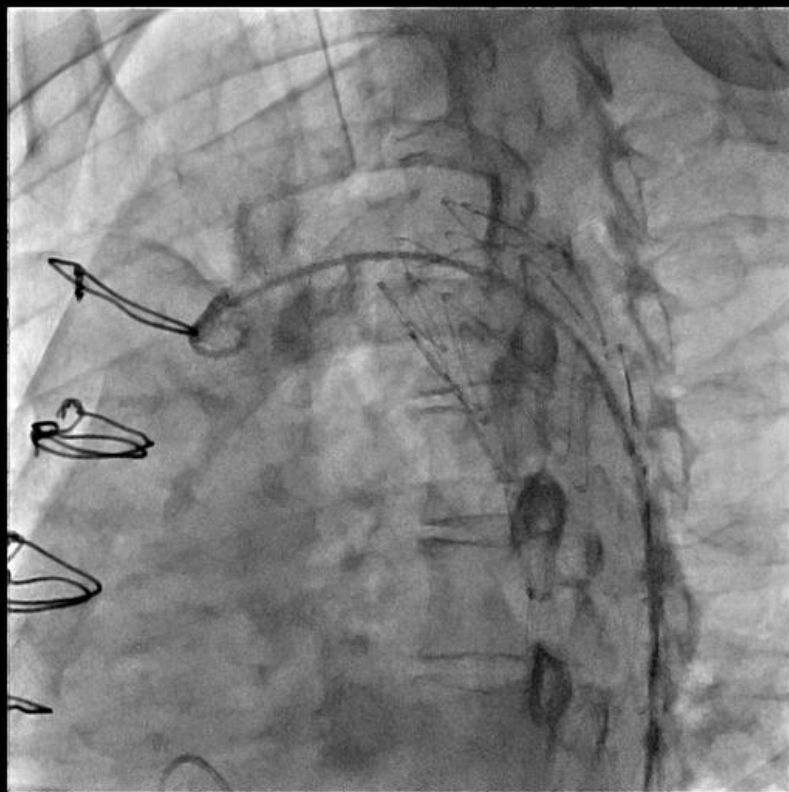


RAO150 CRA0

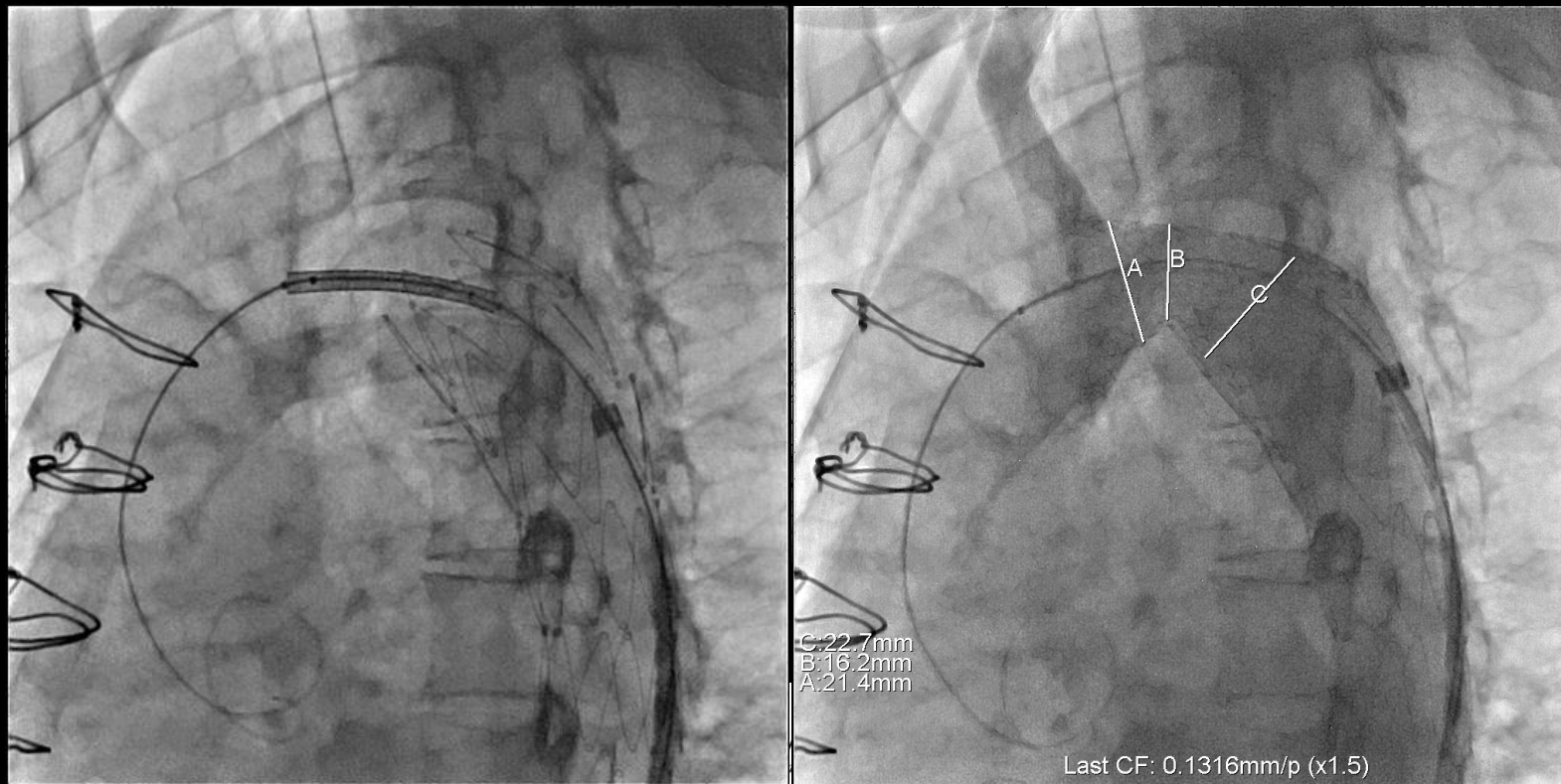
RAO25 CRA69



Vitrea®
Zoom: 148%
Win: 7567
Segmented
VR: All

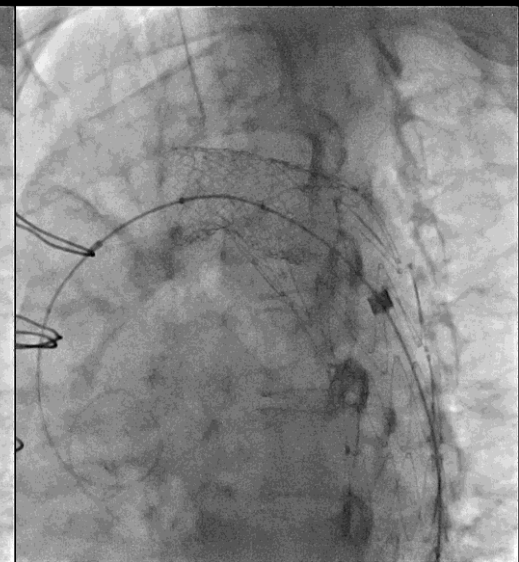
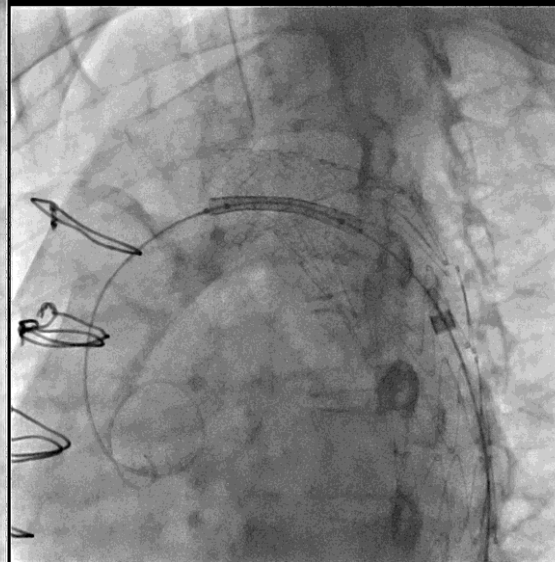
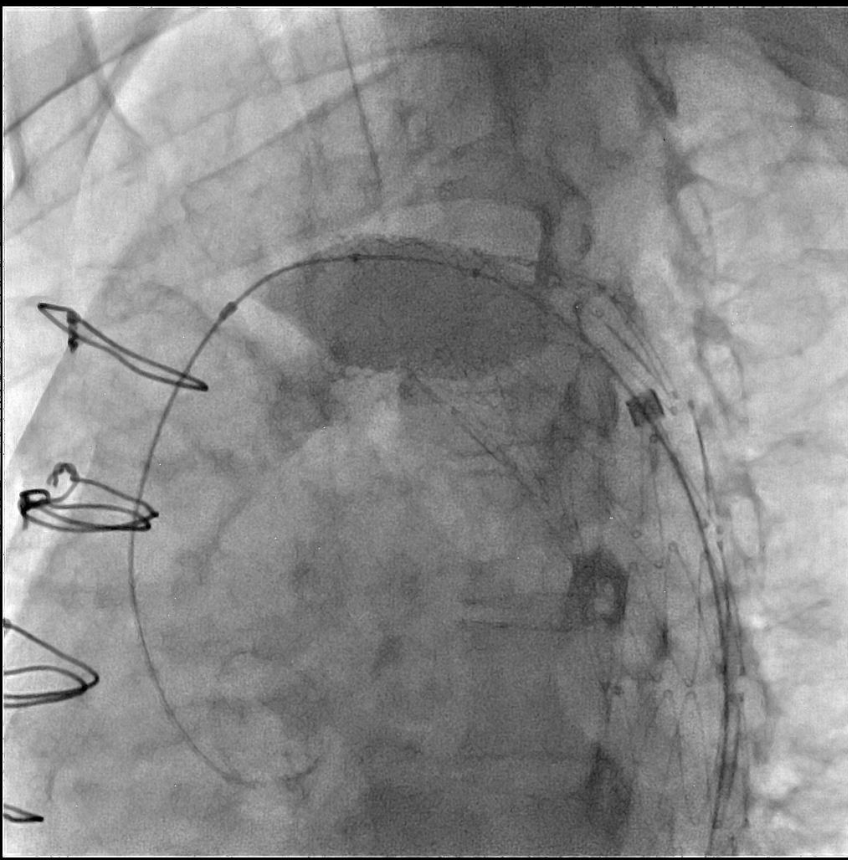


36mm long Max LD on 20mmX4cm BIB

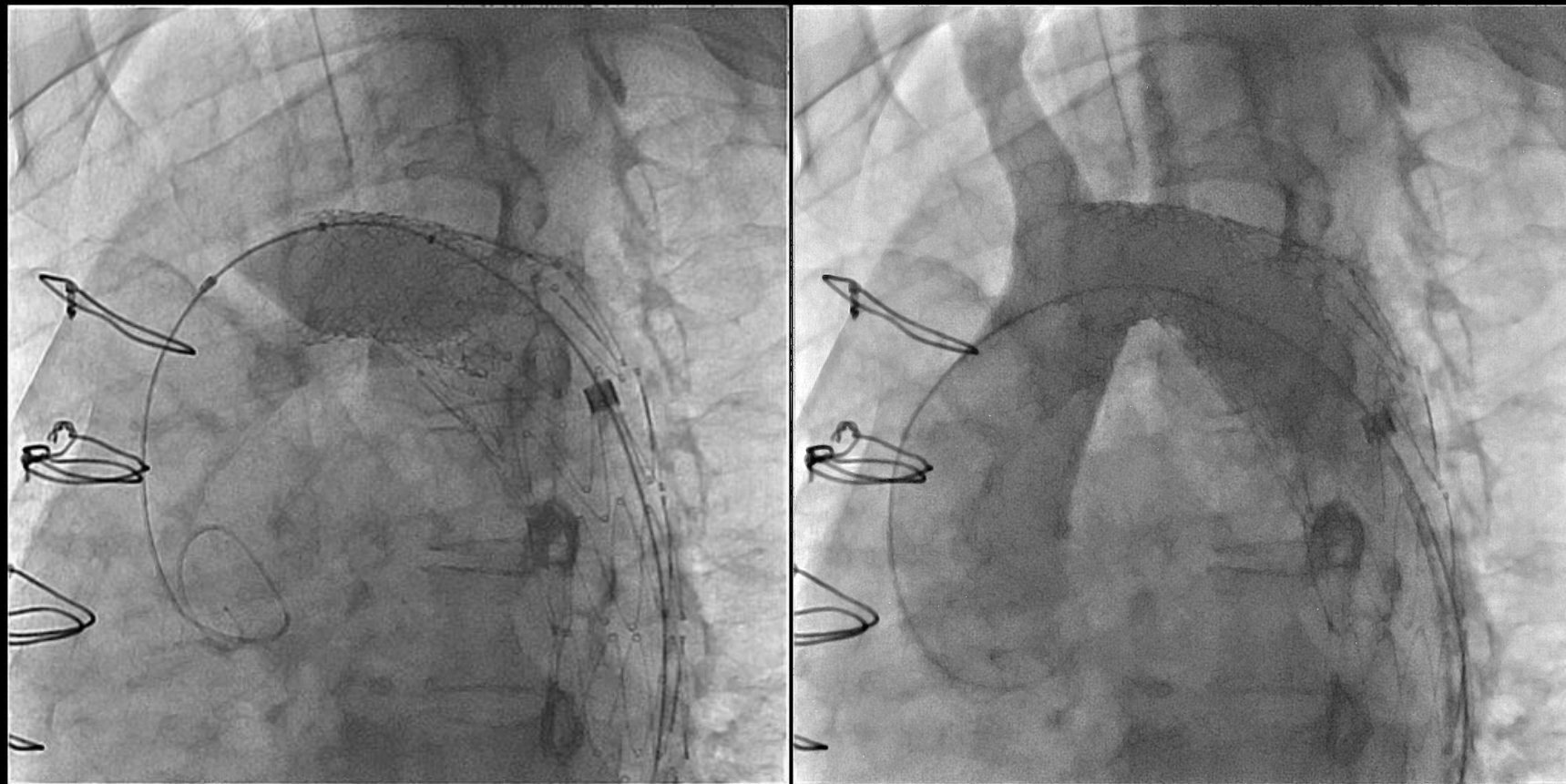


20mm Atlas

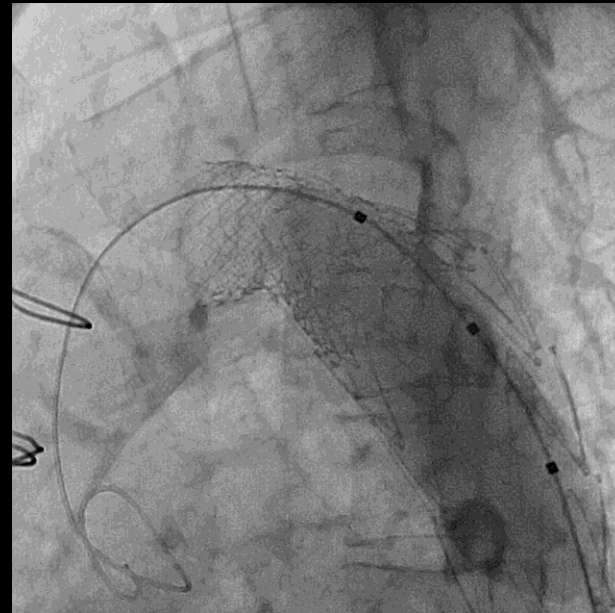
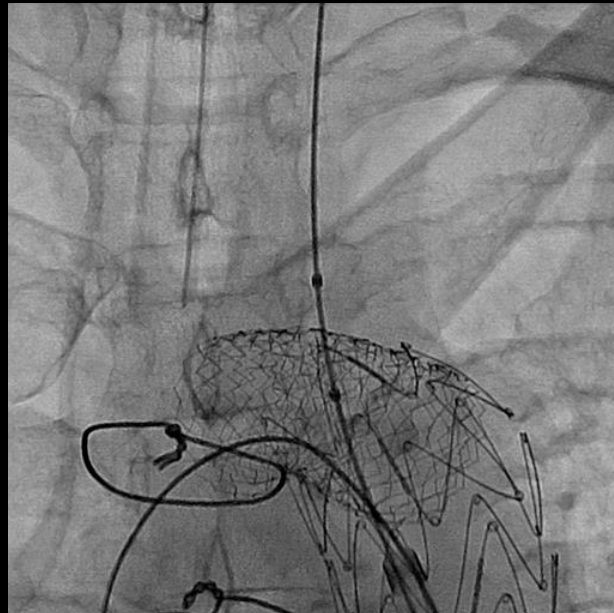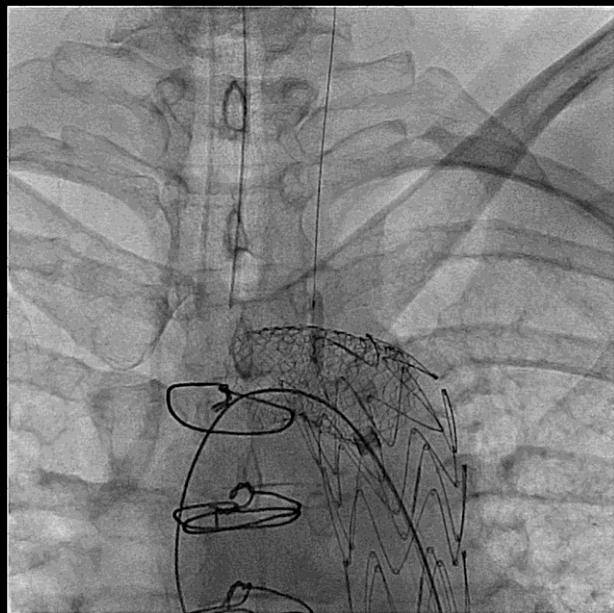
Recoil --> 2nd Stent



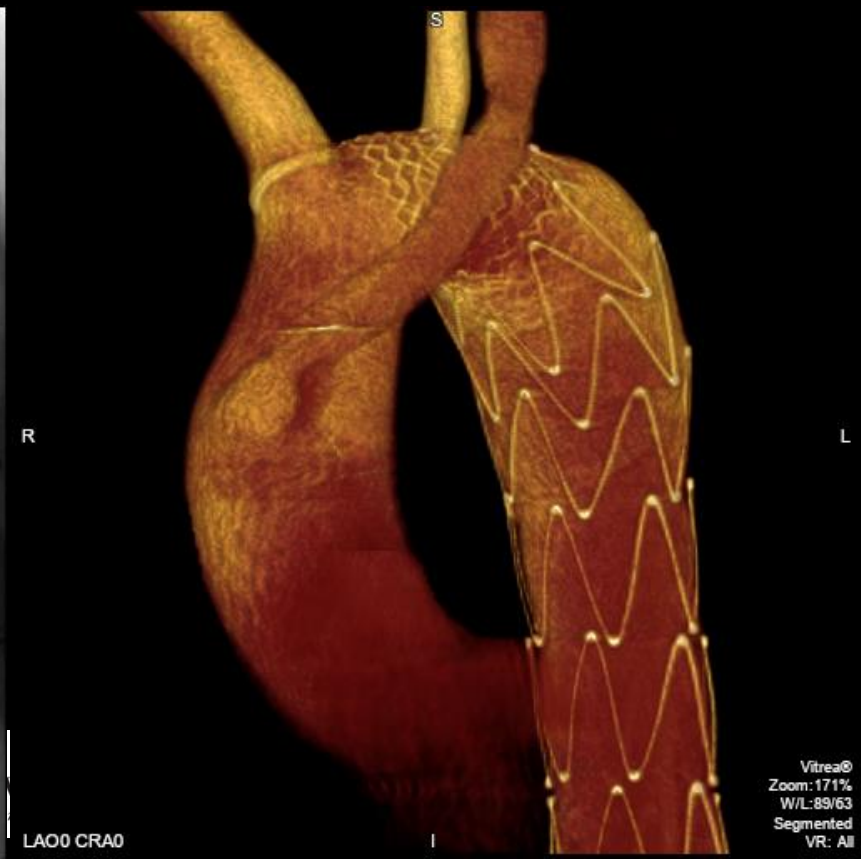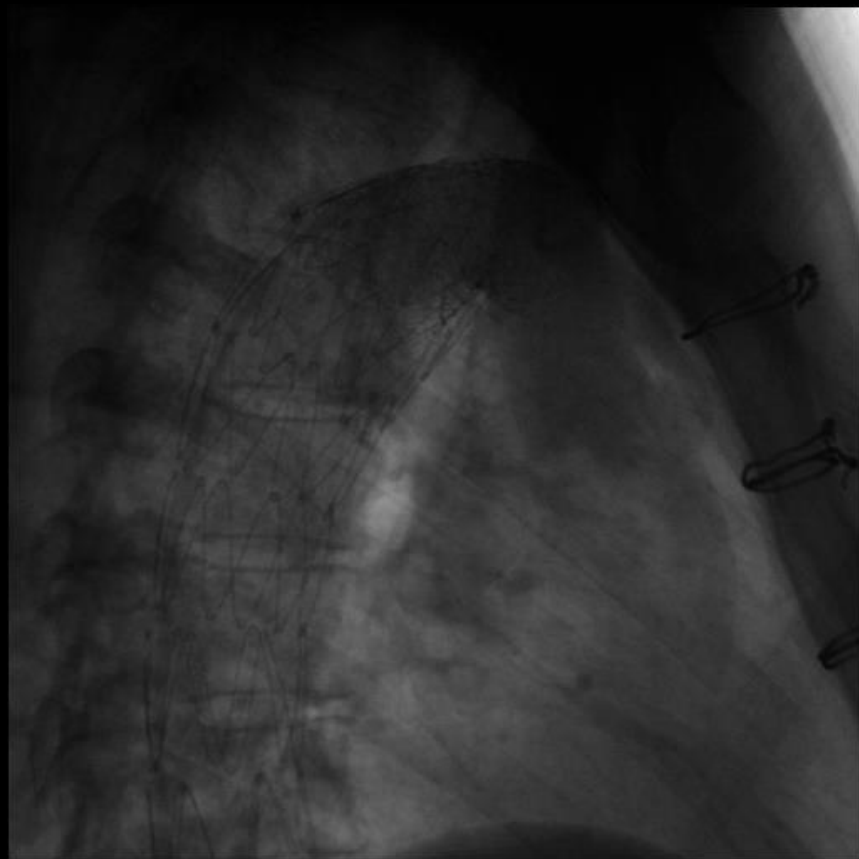
Post-dilation with same 20mm Atlas balloon



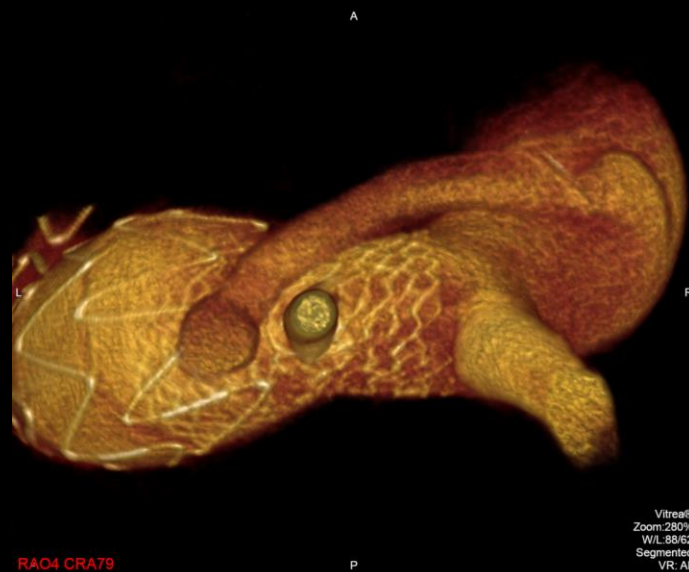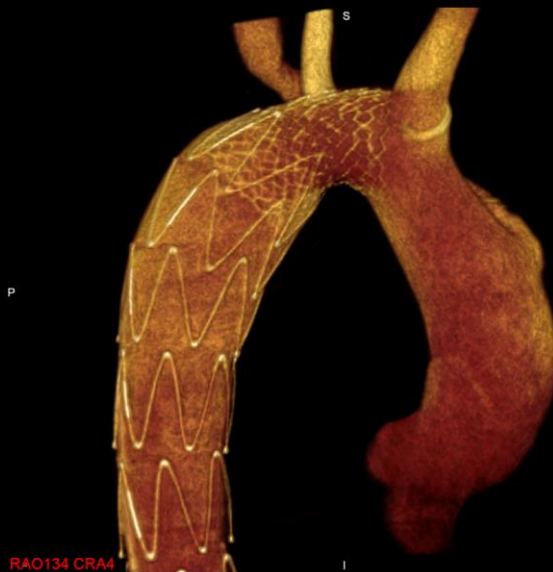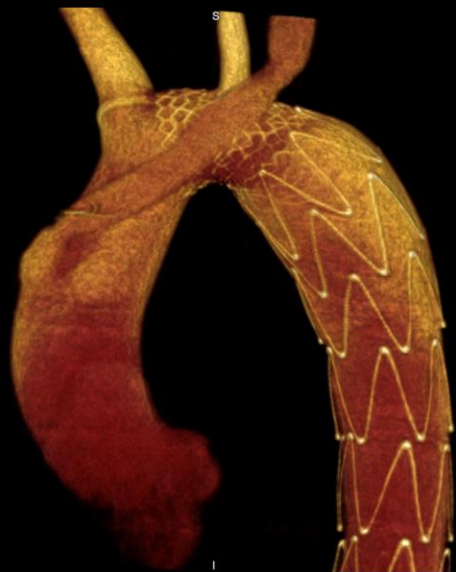Dilated struts crossing the LCCA w/CA 30mm Nucleus balloon followed by 8mm Opta Pro balloon



3DRA, post-intervention



The Heart Center



Vitreag®
Zoom:280%
W/L:88/62
Segmented
VR: All

Endovascular Stenting in Transverse Aortic Arch Hypoplasia The Heart Center

Kuberan Pushparajah,¹ BMBS, BMedSci, Masood Sadiq,² MBBS, FRCP, FRCPCH,
Grażyna Brzezińska-Rajszyś,³ MD, PhD, John Thomson,⁴ BM, BS, B Med Sci, MD, FRCP, FSCAI,
Eric Rosenthal,¹ MD, FRCP, and Shakeel A. Qureshi,^{1*} MBChB, FRCP, FRCPCH

- Retrospective review; 4 centers; from 2000-2010
- Outcomes for stenting of transverse aortic arch hypoplasia
 - reduction in peak systolic catheter gradient
 - dimensions of the stented segment
 - systolic right arm blood pressure
- Early and late complications were recorded
- 21 patients (16 male, 5 female)
 - Median age of 16.5 years (range, 0.25–25.9 years), (2 neonates)
 - Median weight of 55 kg (range, 4.5–103 kg)

Catheterization and Cardiovascular Interventions 82:E491–E499 (2013)



NATIONWIDE CHILDREN'S
When your child needs a hospital, everything matters.™

Results

- **Median transverse arch diameter**
 - Increased from 7 to 14 mm after stenting ($P < 0.001$)
- **Median TAA/DAO at the level of the diaphragm improved**
 - 0.43 to 0.9 ($P < 0.001$)
- **Mean gradient across the hypoplastic TAA decreased**
 - 38 mmHg (14–76) to 5 mmHg (0–13) ($P < 0.001$)
- **No deaths**
- **6 early complications occurred in 5 patients**

Catheterization and Cardiovascular Interventions 82:E491–E499 (2013)



Results: Vessels covered

- Left common carotid artery 2
- Left subclavian
 - Partial 5
 - Total 6
- None 6
- All 2
 - both neonates; prior IAA repair

Catheterization and Cardiovascular Interventions 82:E491–E499 (2013)

Results: Most recent follow up

- N= 19/21 patients
- Median follow-up → 24 months
- Median systolic blood pressure
 - 153 mmHg (117–180) pre-stent
 - 130 mmHg (105–150) post-stent (P < 0.0002)
- 13 patients → Antihypertensive medication could be reduced

Catheterization and Cardiovascular Interventions 82:E491–E499 (2013)



Acute/Early Adverse Events

6 in 5 patients (28.6%)

- 3 major
 - Stent migration – 2
 - Stroke – 1
- 3 minor
 - Transient brachial plexus injury – 1
 - Blood transfusion – 1
 - Bacteremia (*S. viridians*) – 1



Adverse Events at last follow up

3 in 2 patients

- Both neonates
 - Stent fracture + intimal hyperplasia – 1
 - Intimal hyperplasia -- 1

Study Conclusions

- Stenting of TAA hypoplasia
 - Technically challenging
 - Good angiographic and haemodynamic results
 - Early improvement in BP control
 - Appears to be sustained in the medium term
- Stenting of TAA hypoplasia in neonates
 - More longer-term complications and interventions
- Longer term follow up is needed

Catheterization and Cardiovascular Interventions 82:E491–E499 (2013)

Stenting Complex Aortic Arch Obstructions

Ralf J. Holzer,^{1,2*} MSc, MD, Joanne L. Chisolm,^{1,2} Sharon L. Hill,^{1,2} ACNP, RN,
and John P. Cheatham,^{1,2} MD, RN

- Retrospective review; single center; from 2002 -2006
- 40 patients; 42 procedures
- Median age of 10 years (16 days - 37 years)
- Aortic arch hypoplasia present in 30/42 procedures (71.4%)

Catheterization and Cardiovascular Interventions 71:375–382 (2008)



Patient Population

Primary aortic arch anomaly	<i>n</i>
Coarctation of the aorta	23/40 pts (57.5%)
Hypoplastic left heart syndrome (variant)	8/40 pts (20.0%)
Hypoplastic aortic arch	5/40 pts (12.5%)
Interrupted aortic arch	4/40 pts (10.0%)

Catheterization and Cardiovascular Interventions 71:375–382 (2008)

Study Results

- Diameter of arch obstruction increased
 - Median of 7.55mm up to a median of 14mm (P < 0.0001)
- Peak systolic gradient reduced
 - Median of 23 mmHg to a median of 2 mmHg (P <0.0001)
- Arch vessels were crossed in 31/42 proc (73.8%)
- Peri-procedural adverse events
 - 13/42 procedures (30.9%)

Catheterization and Cardiovascular Interventions 71:375–382 (2008)



Peri-Procedural Adverse Events

13/42 procedures (30.9%)

Incidence of adverse events in patients <10 kg:

81.8% vs. 12.9%, $p < 0.0001$

- 5 – Hemodynamic instability requiring inotropes and/or compression
- 2 – Peripheral arterial complication requiring treatment
- 1 – Chest exploration (already on ECMO; increased bleeding at cannula site)
- 2 – Blood transfusion
- 1 – Stent migration requiring another stent
- 1 – Atrial arrhythmia
- 1 – Loss of capture of existing pacemaker



Study Results

- Median follow-up was 1 year (32 days - 3.8 years)
- Incidence of systemic hypertension reduced
 - 22/42 (52.4%) before the procedure
 - 6/39 (15.4%) at most recent follow-up ($P = 0.0005$)
- CT or MRI evaluations
 - Performed in 18 pts
 - All crossed arch vessels appear patent

Catheterization and Cardiovascular Interventions 71:375–382 (2008)

Adverse Events in Follow up (N=38)

- Those with stent crossing innominate and/or LCCA
 - No neurological events (No routine neuroimaging)
- Chest CT or MRI in 18 pts
 - Mild instent stenosis -- 4/18 studies (22.2%)
 - Additional areas of arch obstructions – 2/18
 - No Stent fracture
 - No aneurysm formation or other vascular compromise



Need more long term data

“Long-Term Outcomes of Percutaneous Intravascular Stent Therapy for Transverse Aortic Arch Hypoplasia”

In process -- multicenter retrospective review



NCH only

Preliminary Data

N=70

64% male

Median age

11yr (0.5mo – 50yr)

Median weight

42.2kg (3.2 – 122kg)



Inclusion Criteria

- All patients who underwent stent implantation to treat aortic arch hypoplasia/obstruction
- Defined as narrowing between
 - First aortic branch (usually the innominate artery)
 - Up to and including where the most distal aortic branch would have been (usually the left subclavian artery)



Exclusion Criteria

- All patients who underwent stent implantation to treat (re)coarctation of aorta
 - Stent does not extend into the aortic arch as defined by the take off of the last aortic vessel

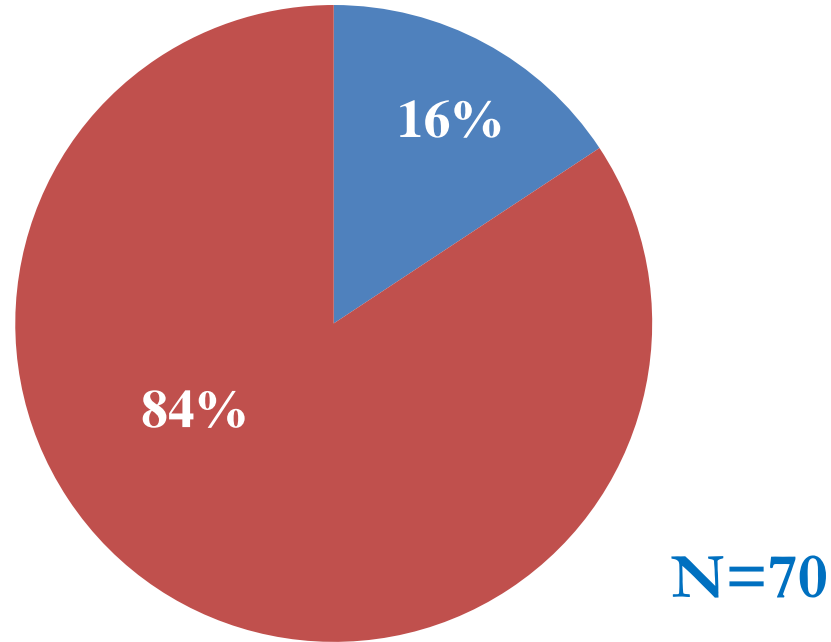
(I.e. if the stent does not cross or partially cross (>50%) the left subclavian artery os, it should be excluded)



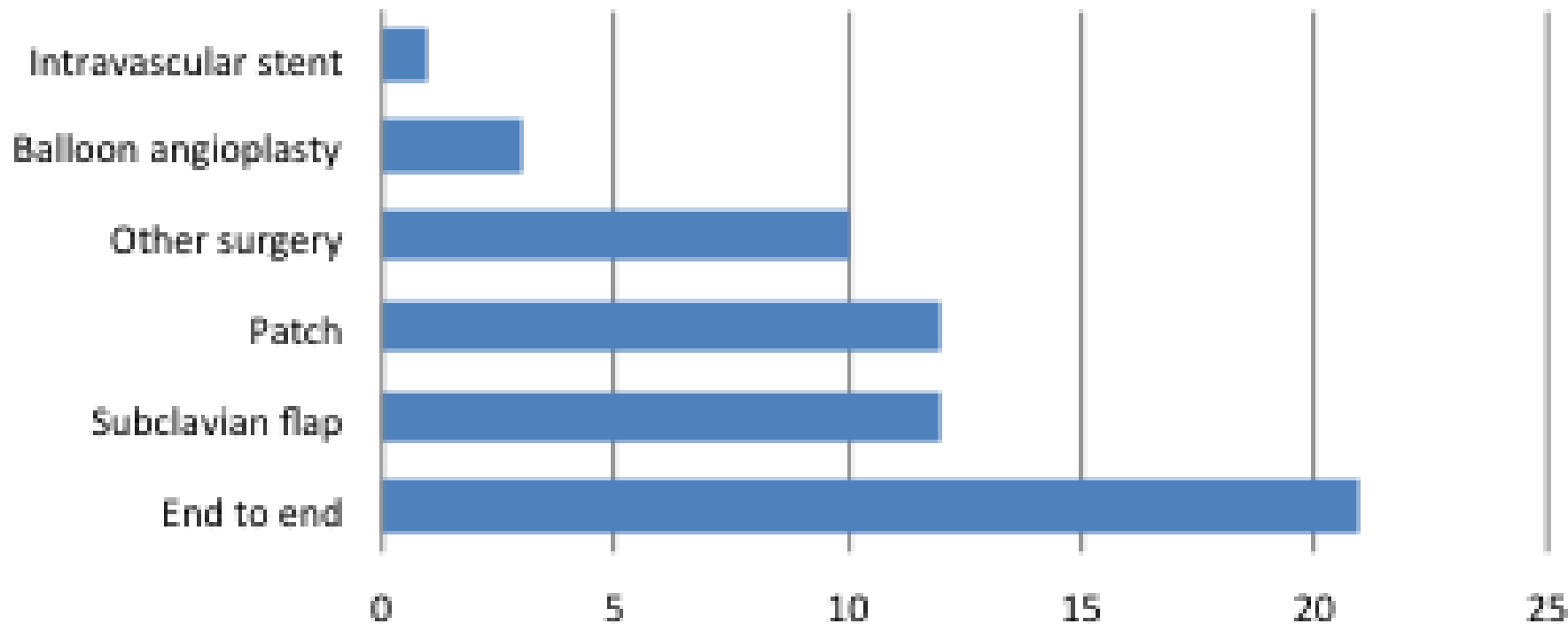
CoA type

The Heart Center

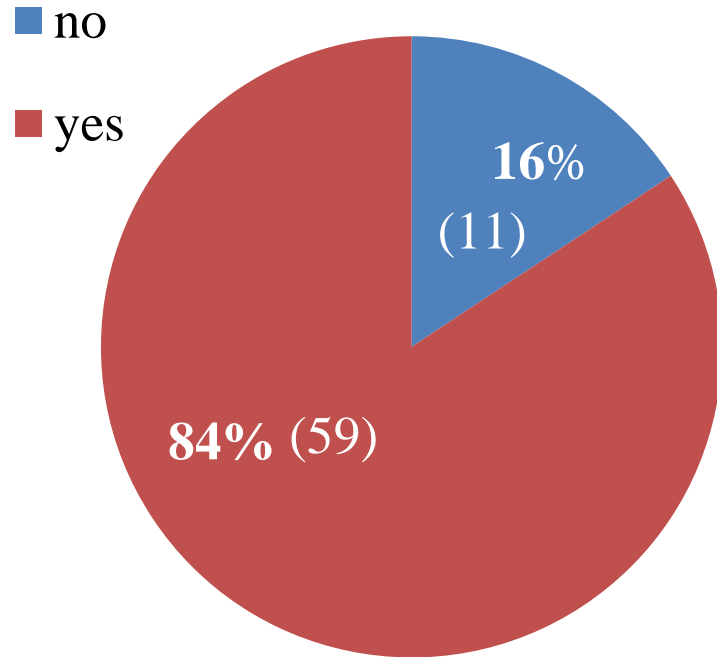
■ Native ■ Re-CoA



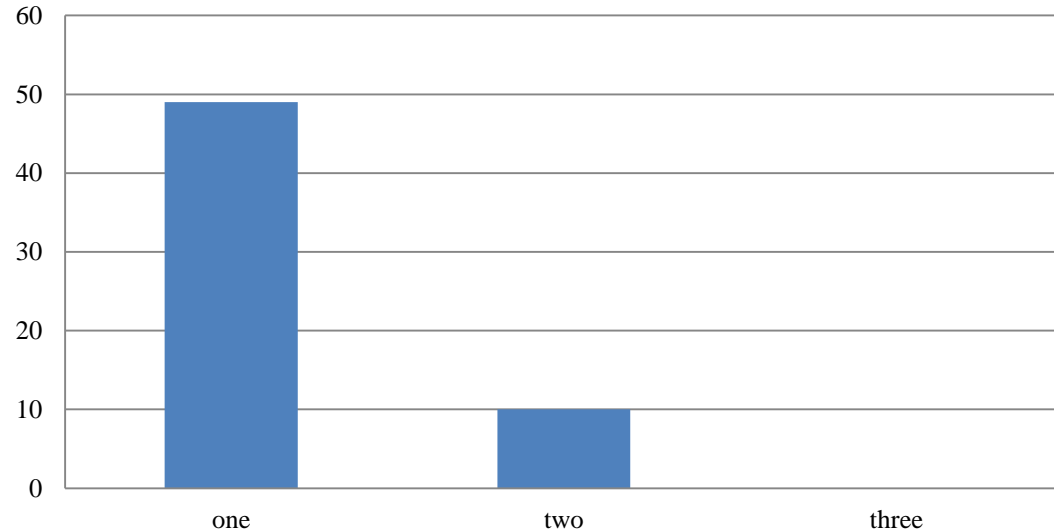
Previous Repair Type



Overlap Arch Vessels

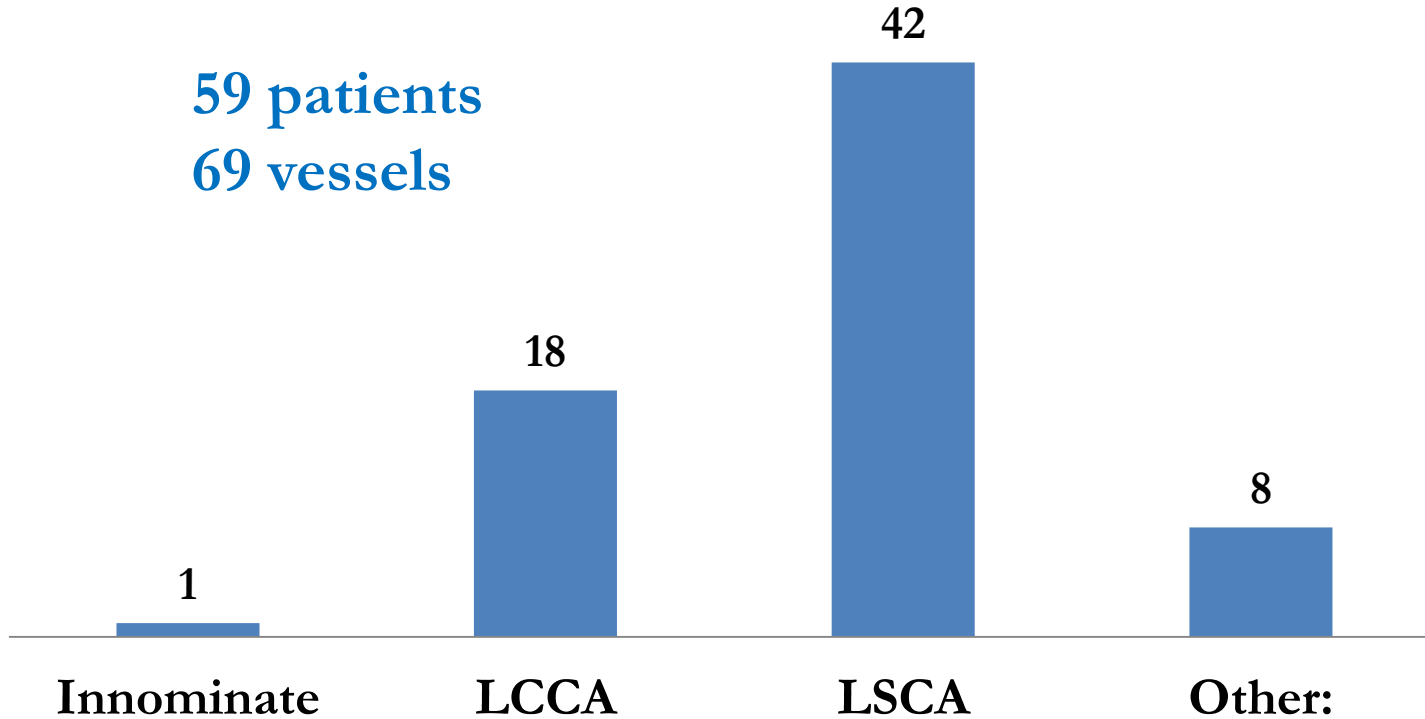


Number of Vessels Covered (n=59)



Vessels Covered

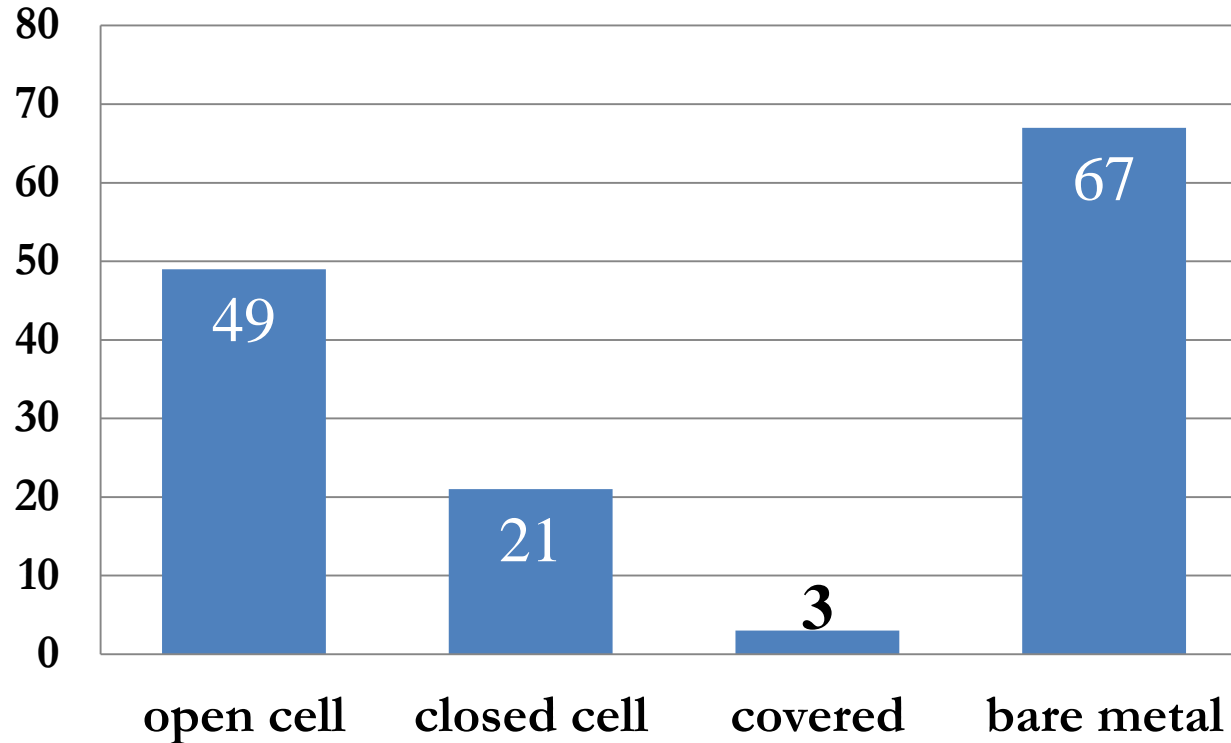
59 patients
69 vessels



Other:
retroeso RSCA
anomalous RSCA
single arch vessel
RSCA
vertebral



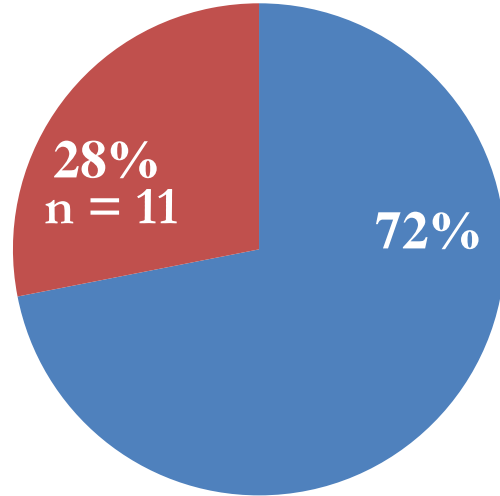
Initial Stent Characteristics



Preliminary Results: Most recent follow up

- N=57 (81.4%)
- Median time to most recent f/u 6.3yrs (1 – 12.9 yrs)
- No neurologic events reported
 - no routine brain imaging

Repeat Intervention Since Stent Implant

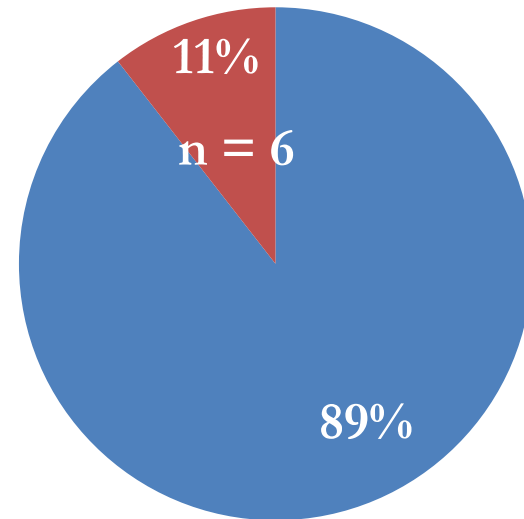


N=57

■ no

■ yes

Stent/Procedure-Related Adverse Events



Stent/Procedure Related Adverse Events

N=6 (11%)

- Stent Fracture (4)
 - Treated with additional stent 3
 - Untreated at this time 1
- Aortic wall injury (2)
 - Wire-related 1
 - Stent-related 1

Conclusions

- Stenting the TAA is feasible and effective
 - Open-celled stents
- Dilate the cells extending across the arch branches
- Medium to long term follow up
 - No reported neurologic events
 - “Acceptable” incidence of stent/procedural-related AE’s
- 3DRA can help in these cases
 - especially complex anatomies





Thank you
Go Dodgers

Bring on the Cubs!



NATIONWIDE CHILDREN'S
When your child needs a hospital, everything matters.™